



Research Article

Post-Retention Changes in Class II Division 1 Malocclusion Extraction Cases: Cephalometric Changes

Surachai Dechkunakorn, Niwat Anuwongnukroh and Kannida Kunakornporamut

Department of Orthodontics, Faculty of Dentistry, Mahidol University, Bangkok, Thailand

Correspondence should be addressed to: Surachai Dechkunakorn; surachai.dec@mahidol.ac.th

Received date: 4 June 2013; Accepted date: 25 September 2013; Published date: 2 December 2013

Academic Editor: Ritu Duggal

Copyright © 2013. Surachai Dechkunakorn, Niwat Anuwongnukroh and Kannida Kunakornporamut. Distributed under Creative Commons CC-BY 3.0

Abstract

Instability of the dental, skeletal and soft tissues is one of the most frequently associated problems with orthodontic correction of Class II division 1 malocclusion. **Objective:** To evaluate the stability of post-retention changes in skeletal type II orthodontic patients with Class II Division 1 malocclusion. **Materials and Methods:** Analysis of cephalometric films was performed for 29 patients with Class II Division 1 malocclusion with skeletal type II (14 males, 15 females, ages ranging from 10.2-18.0 years), who were treated with extractions of four premolars and edgewise-fixed orthodontic appliance. Twenty-six cephalometric variables of dental, skeletal and soft tissues were evaluated at three points of time: pre-treatment, post-treatment and post-retention period (mean, 4.15 years). Repeated measures ANOVA was used to compare the results of pre-treatment and post-treatment periods, and post-treatment and post-retention periods with level of significance set at $p \leq 0.05$. **Results:** The findings of the cephalometric data revealed that significant changes occurred in incisors inclination and position, ratio of facial height and soft tissue profile in the post-treatment period. However in the post-retention period, slight changes in dental, vertical skeletal profile and soft tissue profile were observed. **Conclusion:** In Class II Division 1 malocclusion treated with extraction of the bicuspid and fixed orthodontics, the overall stability of the dental, skeletal and soft tissues in the post-retention period was relatively good.

Keywords: Post-retention changes, Class II Division 1 extraction, Cephalometric measurement

Introduction

In orthodontic therapy, the main objectives are to establish well-functioning occlusion,

facial esthetics and stability after treatment. Many techniques and materials have been developed to improve the results of orthodontic treatment. However,

determining if the occlusion provided at the end of active treatment is harmonious with the patient's biological system and conducive to long term stability is difficult. Class II malocclusion is one of the most common problems seen by orthodontists. Suchato and Chaiwat(1981) found the prevalence of Class II malocclusion among Thai adults to be 14.36% . Many cases following orthodontic treatment of Class II Division 1 relationship show a tendency to return to the original malocclusion(Kingsley,1880; Shapiro,91974). This undesirable phenomenon may occur independently at the type of appliance used, the patient's age during the treatment and the mode of therapy (with or without extraction). Several long-term studies have been performed among Caucasians; however, post-retention stability of orthodontic treatment in Thai patients with Class II malocclusion has not been studied. These studies are necessary because they help to examine the results of the orthodontic correction as well as the long-term outcome of the therapy. The findings could also further increase our knowledge on relapse and reveal possible predictors or clinical guidelines.

Therefore, the purpose of this study was to examine changes in the cephalometric parameter in dental, skeletal direction and soft tissue profile in pre-treatment, post-treatment and post-retention periods following orthodontic correction of Class II Division 1 malocclusion.

Materials & Methods

This study consisted of retrospective analysis of 29 patients with Class II Division 1 (14 males and 15 females) skeletal type II malocclusion who were treated with extraction of four premolars and edge-wise fixed orthodontics. All subjects had complete

set of clinical records, study models and lateral cephalograms at all three periods: pre-treatment (T1), post-treatment (T2) and post-retention (T3).

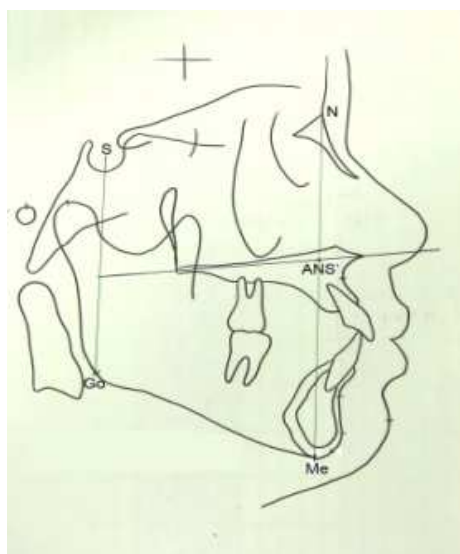
Twenty-nine patients were enrolled in the study based on the following criteria:

- (1) ANB more than 4° (Dechkunakorn et al., 1992),
- (2) Wits appraisal (AO-BO) more than 1 mm (Dechkunakorn et al., 1992),
- (3) Overjet more than 3 mm,
- (4) All teeth present (except third molars),
- (5) Four premolars extracted for treatment purpose,
- (6) Acceptable treatment results: Angle's Class I molar and canine relationship, normal overjet and overbite (1-3 mm) and satisfactory irregularity index (less than 3.5 mm, described as mild crowding (Little, 1975), and
- (7) Postretention period of at least one year or more (Gardner and Chaconas,1976)

Cephalometric Radiographs

Three lateral cephalograms (pre-treatment, post-treatment and post-retention) of the patients were traced and the landmarks were highlighted for digitization purpose. Each cephalometric radiograph was traced and digitized by a single examiner and was confirmed by two experienced orthodontists. All cephalometric variables were computed by Dentofacial planner software, Version 5.3.2, according to 68 lateral standards. The selected measurements in this study included the following:

Skeletal measurements comprised SNA, SNB, ANB, AO-BO, SN-PP, SN-MP, PP-MP, midface length, mandibular length, PFH/AFH, facial index and LAFH/TAFH (Fig.1).



$$\begin{aligned} \text{PFH/AFH} &= \text{S-GO/N-ME} \\ \text{Facial index} &= \text{N-ANS'/ANS'-Me} \\ \text{LAFH/TAFH} &= \text{ANS'-Me/N'-Me} \end{aligned}$$

Fig.1. Measurements of Cephalometric Ratio

Dental measurements comprised U1 to NA, U1 to Apog, U1 to SN, U1 to PP, L1 to-NB, L1 to Apog, L1 to MP and interincisal angle.

Soft tissue measurements comprised upper lip to E-Line and lower Lip to E-Line. All cephalometric parameters compared pre-treatment and post-treatment changes (T2-T1) and post-treatment and post-retention changes (T3- T2) of each variable.

Statistical Analysis

Means and standard deviations were calculated for all variables. Independent t-test was used to compare the difference in sex distribution at pre-treatment period. Repeated measures ANOVA was used to test the difference between pre-treatment and post-treatment periods and post-treatment and post-retention periods. The level of statistical significance was set at $p < 0.05$

Error Control

Double determination to control error was performed on ten sets of randomly chosen lateral cephalograms. Each film in the series (T1, T2 and T3) was retraced and redigitized. The errors were calculated by Paired t-test. All measurements were performed by one examiner within one week interval of the first and second measurements.

Results

Double determination to control measurement errors was not significant ($p < 0.05$) for any measurement.

Table I shows the mean age of total subjects was 13.84 ± 2.24 years (14.25 ± 2.15 years for males and 13.50 ± 2.35 years for females). The mean treatment time was 2.76 ± 1.17 years (2.55 ± 0.84 years for males and 2.94 ± 1.42 years for females). The mean retention time was 0.77 ± 0.41 years (0.73 ± 0.25 years for males and 0.81 ± 0.53 years for females). Finally, the mean post-retention time was 4.15 ± 2.33 years (4.54 ± 1.99 years for males and 3.80 ± 2.62 years for females).

TABLE I: Age, Treatment, Retention and Post-Retention Time of All Subjects

Time	MALE (n=14)		FEMALE (n=15)		TOTAL (n=29)		
	Mean	S.D.	Mean	S.D.	Range	Mean	S.D.
Age (yr)	14.25	2.15	13.50	2.35	10.2 - 18.0	13.84	2.24
Treatment time (yr)	2.55	0.84	2.94	1.42	1.5 - 5.8	2.76	1.17
Retention time (yr)	0.73	0.25	0.81	0.53	0.1 - 2.0	0.77	0.41
Post-retention time (yr)	4.54	1.99	3.80	2.62	1.3 - 8.7	4.15	2.33

TABLE II: Cephalometric Measurements for Pre-Treatment Period in Male and Female Subjects

Measurement	MALE(n=14)		FEMALE (n=15)		p-value
	Mean	S.D.	Mean	S.D.	
Angular measurements (degree)					
SNA	83.77	5.01	84.25	3.91	NS
SNB	77.56	4.97	77.56	3.39	NS
ANB	6.20	1.24	6.71	1.63	NS
U1 to NA	28.45	6.46	27.00	7.37	NS
U1 to Apog	41.25	6.57	41.01	9.91	NS
U1 to SN	112.22	9.03	111.24	9.17	NS
U1 to PP	122.96	6.92	121.20	8.35	NS
L1 to NB	36.52	5.04	35.41	4.96	NS
L1 to Apog	29.92	5.25	28.10	4.48	NS
L1 to MP	101.00	7.14	98.30	4.81	NS
Interincisal angle	108.82	7.48	110.89	9.75	NS
SN - PP	10.71	3.57	9.96	3.09	NS
SN - MP	36.62	6.42	37.91	4.39	NS
PP -MP	25.90	5.93	27.94	4.03	NS
Linear measurements (mm.)					
AO - BO	2.99	2.25	2.54	2.45	NS
U1 to NA	7.31	2.95	6.46	2.80	NS
U1 to Apog	12.48	2.90	11.95	3.51	NS
L1 to NB	10.70	2.16	9.84	2.09	NS
L1 to Apog	5.87	2.20	5.11	2.10	NS
Midface length	95.99	5.76	90.89	4.91	*
Mandibular length	121.77	6.92	115.88	5.20	*
Upper lip to E-line	3.48	1.89	2.90	2.06	NS
Lower lip to E-line	5.73	1.84	5.10	2.15	NS
Ratios (percent)					
PFH/AFH	63.32	4.65	61.62	3.74	NS
Facial Index	83.05	6.59	82.59	5.02	NS
LAFH/TAFH	54.67	1.95	54.80	1.51	NS

Sig. at $p < 0.05^*$

Table II shows the differences of 26 lateral cephalogram variables in male and female subjects. Significant differences were found only in the midface and mandibular lengths at pre-treatment. Most variables had no difference between sexes; therefore, the male and female samples were combined as a single sample. The samples were computed

for all 26 cephalometric variables. Descriptive statistics and repeated measures ANOVA for angular, linear and proportional cephalometric measurements in the sample groups at pre-treatment, post-treatment and post-retention periods are presented in Table III.

TABLE III: Treatment Changes: Descriptive and Inferential Statistics for Cephalometric Measurements

Measurement	T1		T2		T3		T2-T1 (Repeated Measures Anova)			T3-T2 (Repeated Measures Anova)		
	Mean	S.D.	Mean	S.D.	Mean	S.D.	Diff.	Std error	p	Diff.	Std error	p
Angular measurements (degree)												
SNA	84.02	4.40	83.26	4.03	83.26	4.37	-0.75	0.24	*	0.00	0.20	NS
SNB	77.56	4.15	77.43	3.93	77.68	3.99	-0.13	0.22	NS	0.25	0.18	NS
ANB	6.46	1.45	5.82	1.54	5.57	1.61	-0.64	0.18	*	-0.24	0.14	NS
U1 to NA	27.70	6.86	14.84	6.82	16.32	7.23	-12.86	1.65	*	1.48	0.70	*
U1 to Apog	41.13	8.32	25.71	6.06	26.43	6.09	-15.41	1.68	*	0.71	0.56	NS
U1 to SN	111.71	8.96	98.09	7.12	99.57	6.64	-13.62	1.73	*	1.47	0.64	*
U1 to PP	122.05	7.61	108.54	5.86	110.16	6.25	-13.51	1.71	*	1.62	0.62	*
L1 to NB	35.95	4.94	31.16	4.37	29.90	4.27	-4.78	1.16	*	-1.25	0.57	*
L1 to Apog	28.97	4.87	26.12	4.25	25.35	3.90	-2.85	1.19	*	-0.76	0.56	NS
L1 to MP	99.61	6.09	94.80	5.35	94.61	5.49	-4.81	1.15	*	-0.18	0.58	NS
Interincisal angle	109.89	8.64	128.17	8.96	128.22	8.83	18.27	2.25	*	0.04	1.01	NS
SN - PP	10.32	3.29	10.42	2.88	10.58	2.67	0.10	0.28	NS	0.15	0.16	NS
SN - MP	37.29	5.40	37.23	5.53	35.98	5.79	0.06	0.31	NS	-1.24	0.31	*
PP -MP	26.95	5.05	26.80	5.09	25.39	5.54	0.15	0.31	NS	-1.41	0.33	*
Linear measurements (mm.)												
AO-BO	2.75	2.33	2.06	1.82	2.87	2.13	-0.68	0.48	NS	0.80	0.32	*
U1 to NA	6.87	2.86	1.35	2.55	2.01	2.79	-5.52	0.65	*	0.66	0.26	*
U1 to Apog	12.21	3.18	6.04	2.20	6.41	2.28	-6.16	0.57	*	0.36	0.19	NS
L1 to NB	10.25	2.13	7.67	2.00	7.46	1.73	-2.57	0.42	*	-0.21	0.21	NS
L1 to Apog	5.48	2.15	3.05	1.95	2.80	1.86	-2.43	0.41	*	-0.24	0.21	NS
Midface length	93.35	5.85	94.80	6.04	95.12	5.75	1.45	0.46	*	0.32	0.38	NS
Mandibular length	118.72	6.69	124.1	6.80	125.13	6.53	5.38	0.66	*	1.02	0.63	NS
Upper lip to E-line	3.18	1.97	0.34	1.85	-0.42	2.02	-2.84	0.25	*	-0.76	0.31	*
Lower lip to E-line	5.41	1.99	2.10	2.69	1.58	2.33	-3.31	0.37	*	-0.51	0.28	NS
Ratios (percent)												
PFH/AFH	62.44	4.22	62.87	4.22	64.08	1.21	0.42	0.21	*	1.21	0.22	*
Facial Index	82.81	5.73	80.47	4.52	80.32	-1.5	-2.33	0.59	*	-0.15	0.30	NS
LAFH/TA FH	54.74	1.71	55.44	1.38	55.50	0.05	0.70	0.18	*	0.05	0.09	NS

Sig. at $p < 0.05^*$

Table III shows the difference in changes after treatment and retention (T2-T1, T3-T2). For post-treatment changes, most cephalometric values were significant ($p < 0.05$) different, except SNB, SN - PP, SN - MP, PP -MP and Wits appraisal. For post-retention changes (T3-T2), significant ($p < 0.05$) differences were found for U1 to NA (degree), U1 to SN, U1 to PP, L1 to NB (degree), SN-MP, PP-MP, Wits appraisal, U1 to NA (mm.), upper lip to E line and PFH/AFH.

Discussion

All subjects at pre-treatment stage of this study had orthognathic maxilla, retrognathic mandible, open configuration, proclination of upper and lower incisors and convex profile compared with Thai norms (Dechkunakorn et al., 1992). From patients' interviews, approximately 50% of the subjects had taken off their retainers before the appropriate period. Retention period in males was 0.73 years, and in females 0.81 years (mean of both was 0.77 years). The possible reason may be attributed to unawareness of the importance of wearing retainers and the weakness of the follow-up system.

Twenty-nine patients had complete documents. The mean age of the subjects (13.84 years) was similar to the studies by Luppanapornlar and Johnston, 1993, 12.88 years and Paquette et al., 1999, 12.53 years. Most orthodontic Class II patients were treated during the parapubertal growth spurt. The post-retention period in this study was 4.15 years, which was shorter compared with studies by Gardner and Chaconas, 1976 (5.3 years) and Harris et al., 1999 (5.5 years).

Skeletal Changes

Most post-treatment changes (T2-T1, Table III) showed significant ($p < 0.05$) differences in cephalometric variables, except SNB, SN-PP, SN-MP, PP-MP and Wits appraisal. SNB values were not significantly different from those reported by Harris et al., 1999 and Basciftci et al., 2003. After treatment the

antero-posterior position of maxilla relative to the cranial base decreased which may have occurred as a result of the remodeling of A point or the anterior movement of N point. Therefore, the ANB correction was primarily due to the decrease of SNA (Merrifield and Cross, 1970; Bennett et al., 1975).

In regard to the post-treatment changes in vertical direction, SN-PP, SN-MP and PP-MP did not change significantly. PFH/AFH, LAFH/TAFH increased significantly and UAFH/LAFH (Facial index) reduced significantly. This could have been because these patients showed the tendency to grow vertically quite equally in the anterior and posterior parts of the face during the treatment.

Mandibular length also showed significant ($p < 0.05$) difference after treatment due to the growth of the mandible in late adolescence (Harris et al., 1999; Hellman, 1927; Nanda, 1955) and the parapubertal growth spurt (Hellman, 1927; Koen, 1981).

After treatment, midface length increased significantly ($p < 0.05$). Behrents, 1984 reported that the change of midface dimension might be attributed to an increase in the nasal airway from the increased physiologic demands brought on by age or due to the downward and forward growth of the maxilla during late adolescence.

In the post-retention period (T3-T2), no significant ($p < 0.05$) changes were found in antero-posterior direction at SNA, SNB and ANB, which was similar to the studies by Luppanapornlar and Johnston, 1993 and Paquette et al., 1992. These observations revealed a small amount of growth during the post-retention period. However, the Wits appraisal of this study increased significantly at post-retention which might be associated to relapse of the functional occlusal plane from orthodontic treatment.

Regarding the post-retention changes, the maxilla showed no difference in the PP plane (SN-PP changed with no significance), but the mandible showed a tendency to grow in an

upward direction (SN-MP decreased significantly, PP-MP decreased significantly and PFH/AFH increased significantly). These results are similar to previous studies by Harris et al.,1999 and Erdinc et al.,2006 , which found that the increase in posterior facial height was more than that of the anterior facial height resulted in a decrease in the two angles of the occlusal planes (Downs' and Functional) to the Frankfort Horizontal Plane. This growth pattern promotes upward and forward mandible rotation and stability of the class II correction from the end of treatment to post-retention period. Many studies have stated that the increase in the PFH/AFH ratio indicates a good prognosis for maintenance of the Class II correction because the consequence of an increasing ratio is an upward and forward (counterclockwise) rotation of the mandible and a flattening of the occlusal plane (Horn,1992; Subtelny et al.,1966; Bjork,1969; Isaacson et al.,1977; Woodside and Linder-Aronson,1979; Neilson,1991). Control of the vertical dimension during correction of a moderate to high angle Class II malocclusion could be the single most important factor influencing favorable mandibular change (Bjork,1969; Isaacson et al.,1977; Neilson,1991) . If vertical control is lost, the mandible can rotate downward and backward, decreasing the potential for a favorable mandibular change. Furthermore, Horn,1992 found that the PFH/AFH ratio is a good indicator of vertical control as active treatment progressed. He stated that an increase in the PFH/ AFH ratio indicates good control of the vertical dimension.

In summary of skeletal changes, the subjects were successfully treated and the increase in posterior facial height also promoted the stability of Class II correction. The increase of posterior facial height may be a good control in the posterior dentoalveolar height, which may result from the forward movement of the molars into the extraction site.

Dental Changes

The cephalometric analysis (Table III, T2-T1) showed that all variable related to upper and lower incisors significant decreased ($p < 0.05$) after treatment, except increase in the interincisal angle. These changes were observed because of the retraction of the upper incisors and slight retroclination of lower incisors to correct the dental overjet and overbite during the treatment (Basciftci and Usumez,2003).

Post-retention changes (Table III, T3-T2) showed a tendency of relapse of the proclined position of the upper incisors; four variables of the upper incisors increased significantly (U1 to NA, U1 to SN, U1 to PP and linear measurement of U1 to NA). Although the angulation and inclination of lower incisors decreased in all measurements, only L1 to NB decreased significantly.

The incisal angulation relapsed because of the changes in the overjet from the relapsed upper incisors and the retroclination of the lower incisors. This result contrasts with the studies by Luppapornlarp and Johnston,1993 and Paquette et al.,1992 , who found that upper and lower incisors continued to retrocline at the post-treatment period. The difference can be attributed to the more uprighted upper incisor position in this study. Overly uprighted or tipped incisors have a tendency to return to their original position. As a result, the clinician should pay attention to the adequacy of lingual root torque of incisors before removing the fixed appliance.

Soft Tissue Profile

At post-treatment period (Table III, T2-T1); upper and lower lip to E line significantly decreased to a more esthetic lip profile because of the changes in the upper and lower incisors. The profiles tend to have straighter faces in extraction cases which are similar to reports by Bishara et al.,1997 and Basciftci and Usumez ,2003 .

For the post-retention changes (T3-T2), upper and lower lip to E line showed improved esthetic profile which decreased further 0.76 and 0.51 mm, respectively, but significant difference was seen only in upper lip to E line. The result is consistent with those of Luppapornlarp and Johnston, 1993. This flattening of the facial profile was evident of maturational changes associated with continued mandibular growth, upward and forward mandibular rotation and growth of the nose and chin (Schudy, 1974; Anderson, 1973; Zierhut et al., 2000).

Overall, the results of this study supported previous findings that only minor relapse is found after Class II correction (Uhde et al., 1983; Hellekant et al., 1989). Although the incisors changed significantly, the other smaller changes in the relationships may not be clinically significant.

Conclusion

The present study aimed to determine the long-term dental, skeletal and soft tissue profile changes in 29 Class II Division 1 with skeletal type II orthodontic patients (14 males and 15 females) treated in combination with the removal of the four premolars and fixed appliance. The results can be summarized as follows: 1) most of the skeletal parameters showed no significant difference between post-treatment and post-retention, except decrease in SN-MP and PP-MP and increase in PFH/AFH ratio, which are the primary factors in the maintenance of the corrected Class II malocclusion; 2) upper incisors tended to procline but lower incisors tended to retrocline after post-retention; 3) upper and lower lip to E-line continued to decrease during post-retention, and 4) the correction of Class II by extracting four premolars showed relatively stable results.

References

- [1] Suchato, W. and Chaiwat, J. (1981), 'Prevalence of malocclusion in young adult,' *Mahidol Dent J*, 2, 133-143.
- [2] Kingsley, NW. (1880), 'Oral Deformities,' New York. D Appleton and Company, 136.
- [3] Shapiro, PA. (1974), 'Mandibular dental arch form and dimension. Treatment and posttreatment changes,' *Am J Orthod*, 66, 58-70.
- [4] Dechkunakorn, S. Sawaengkit, P., Anuwongnukroh, N. Sonthilawat, P. (1975), 'Correspondence of antero-posterior jaw relation indicators,' *J Dent Assoc Thai*, 42, 62-68.
- [5] Little, RM. (1975), 'The Irregularity Index: A quantitative score of mandibular anterior alignment,' *Am J Orthod*, 68, 554-563.
- [6] Gardner, SD. and Chaconas, SJ. (1976), 'Posttreatment and postretention changes following orthodontic therapy,' *Angle Orthod*, 46(2), 151-161.
- [7] Luppapornlarp, S. and Johnston, LE. (1993), 'The effects of premolar-extraction: A long-term comparison of outcomes in "clear-cut" extraction and nonextraction Class II patients,' *Angle Orthod*, 63, 257-272.
- [8] Paquette, DE., Beattie, JR. and Johnston, LE. (1992), 'A long-term comparison of non-extraction and premolar extraction edgewise therapy in "borderline" Class II Patients,' *Am J Orthod*, 102(1), 1-14.
- [9] Harris, EH., Gardner, RZ. and Vaden, JL. (1999), 'A longitudinal cephalometric study of postorthodontic craniofacial changes,' *Am J Orthod*, 115, 77-82.
- [10] Basciftci, FA. and Usumez, S. (2003), 'Effects of extraction and nonextraction treatment on Class I and Class II subjects,' *Angle Orthodontist*, 73, 36-42.

- [11] Merrifield, LL. and Cross, J. (1970), 'Directional forces,' *Am J Orthod*, 57, 435-464.
- [12] Bennett, TH., Tullock, TFC., Vig, KWL. and Webb, WG. (1975), 'Overjet stability after treatment of Class II division 1 malocclusion,' *Br J Orthod*, 2, 239-246.
- [13] Hellman, M. (1927), 'Changes in the human face brought on by development,' *Int J Orthod*, 13, 475-516.
- [14] Nanda, R. (1955), 'The rates of growth of several facial components measured from serial cephalometric roentgenograms,' *Am J Orthod*, 41, 658-673.
- [15] Koen, MC. (1989) Use of skeletal maturity indicators to enhance growth prediction during adolescence (Master's Thesis) Memphis: University of Tennessee.
- [16] Behrents, RG. (1984) A treatise on the continuum of growth in the aging craniofacial skeleton (PhD Dissertation). Ann Arbor: University of Michigan.
- [17] Erdinc, A.E., Nanda, RS. and Isiksal, E. (2006), 'Relapse of anterior crowding in patients treated with extraction and nonextraction of premolars,' *AJODO*, 129, 776-784.
- [18] Horn, A. (1992), 'Facial height index,' *Am J Orthod*, 102, 180-186.
- [19] Subtelny, Ill. and Sakuda, M. (1966), 'Muscle, oral malformation, and growth changes,' *Am J Orthod*, 52, 495-517.
- [20] Bjork, A. (1969), 'Prediction of mandibular growth rotation,' *Am J Orthod*, 55, 585-599.
- [21] Isaacson, RJ., Zapfel, RJ., Worms, FW. and Erdman, AG. (1977), 'Effects of rotational jaw growth on the occlusion and profile,' *Am J Orthod*, 72, 276-286.
- [22] Woodside, DG. and Linder-Aronson, S. (1979), 'The channelization of upper and lower anterior face heights compared to population standards in males between ages 6-20 years,' *Eur J Orthod*, 1, 214-240.
- [23] Nielson, IL. (1991), 'Vertical malocclusions: etiology, development, diagnosis and some aspects of treatment,' *Angle Orthod*, 61, 247-260.
- [24] Bishara, SE., Cummins, DM. and Zaher, AR. (1997), 'Treatment and posttreatment changes in patients with Class II, Division 1 malocclusion after extraction and nonextraction treatment,' *AJODO*, 111, 18-27.
- [25] Schudy, FF. (1974), 'Posttreatment craniofacial growth: its implications in orthodontic treatment,' *Am J Orthod*, 65, 39-57.
- [26] Anderson, JP., Joondeph, DR. and Turpin, DL. (1973), 'A cephalometric study of profile changes in orthodontically treated cases ten years out of retention,' *Angle Orthod*, 43, 324-336.
- [27] Zierhut, EC., Joondeph, DR., Artun, J. and Little, RM. (2000), 'Long-term profile changes associated with successfully treated extraction and nonextraction Class II Division 1 malocclusions,' *Angle Orthod*, 70, 208-19.
- [28] Uhde, MD., Sadowsky, C. and BeGole, EA. (1983), 'Long-term stability of dental relationships after orthodontic treatment,' *Angle Orthod*, 53, 240-252.

- [29] Hellekant, M., Lagerstrom, L. and Glerup, A. (1989), 'Overbite and overjet correction in a Class II Division 1 sample treated with edgewise therapy,' Eur J Orthod,11,91-106