



Research Article

Plastination: An Intricate and Real Display of Oral Hard and Soft Tissue Specimens

Megha Jain¹, Sowmya Kasetty² and Sudheendra U S³

¹Department of Oral and Maxillofacial Pathology, Peoples Dental Academy, Bhopal, Madhya Pradesh, India

²Department of Oral and Maxillofacial Pathology, Peoples College of Dental Sciences and Research Center, Bhopal, Madhya Pradesh, India

³Department of Oral and Maxillofacial Pathology, Coorg institute of Dental Sciences, Virajpet, Karnataka, India

Correspondence should be addressed to: Megha Jain; megha.vipin12@gmail.com

Received 17 July 2013; Accepted 1 August 2013; Published 24 January 2014

Academic Editor: Prasanna Neelakantan

Copyright © 2014 Megha Jain, Sowmya Kasetty and Sudheendra U S. Distributed under Creative Commons CC-BY 3.0

Abstract

Basic theory behind plastination is to halt the natural ongoing process of decomposition triggered by cellular enzymes in tissues that have been removed from the body of deceased individuals. In this technique biological specimens are impregnated with reactive polymer which replaces all the water and fat giving them physical state approaching living condition and can also be used for electron and light microscopic studies. So the present study was aimed to perform and assess the efficacy of plastination technique in preservation of oral soft tissue specimen for museum purposes and in demonstration of root canal morphology of teeth. Moreover, physical and dimensional changes, in both tooth and soft tissue specimens after each process was also evaluated.

Extracted teeth with formalin fixed pulp and formalin fixed soft tissue specimens were taken. Teeth were decalcified first. Both type of specimens were then taken for dehydration, clearing and plastination.

Shrinkage was noted following procedures of decalcification, dehydration and clearing. The procedure of plastination resulted in shrinkage in soft tissue specimen but no appreciable changes were noted in tooth specimens. Notwithstanding the problem of shrinkage, plastination offers several advantages over other methods used for study of root canal morphology and over conventional museum techniques for preservation of soft tissue specimens. Thus, plastination proved to be a beautiful admixture of science and art aimed for educational purpose to both the dental students and for the patient education and an excellent museum technique.

Keywords: Plastination, Decalcification, Methsalicylate, Clearing, Embalming paste.

Introduction

Plastination was invented in 1978 at the University of Heidelberg by Doctor Gunther von Hagens. Since its prologue, it has gained wide acceptance all over the world and the first paper describing this innovative method was published by Dr. von Hagens himself in 1979 (von Hagens G 1979). Plastination is a combination of science, technological phenomenon and artistic events in association with cultural aspects of life and death (Pashaei S 2010).

The process of plastination primarily involves replacement of water and lipids in biological tissues by curable polymer which is subsequently hardened. The procedure consists of the following steps - fixation, dehydration, forced impregnation in a vacuum and hardening. The ultimate properties of the finished specimen are determined by the class of polymer used which may consist of silicone, epoxy-silicone or epoxy resins (von Hagens G 1987).

Plastinated specimens are now considered as milestone in medical education. They have become an ideal teaching tool not only in anatomy but also in pathology, obstetrics, radiology and surgery (Saeed et al 2001, Al-Zuhair et al 1995). Plastinated specimens have several advantages over formalin preserved ones in that the former are clean, dry, odorless, durable, non-toxic, non-infectious, do not exude fumes or fluid, have superior esthetics, can act as patient educational tool, can be handled without gloves and do not require any special storage conditions or care (Latorre R. M 2007, Ravi SB 2011). Moreover studies have shown that plastinated specimens can be used for both light microscopy and ultra-structural studies following deplastination thus allowing retrospective epidemiological studies of archived pathology specimens (Grondin G et al 1994). Literature search revealed very few studies (Aufdemorte TB et al 1985, Vidya M et al 2009) concerning plastination of oral soft tissue specimens. With regards to plastination of teeth specimens we were unable to find any studies. Therefore present study aimed to

perform and assess the efficacy of plastination technique in demonstration of root canal morphology of teeth and preservation of oral soft tissue specimen for museum purposes. Also, an attempt was made to evaluate dimensional changes in both hard and soft tissue specimens after each step of plastination procedure.

Materials

Materials required included extracted teeth, soft tissue specimen, formalin, nail enamel paint, disposable tea cups, red ink, hydrogen peroxide (for cleaning purpose), 5% nitric acid (for decalcification process), alcohol and acetone (both for dehydration purpose), methyl salicylate (for clearing process), xylene (for making embalming paste).

Methodology

Clearing and Plastination of Tooth Specimen:

20 freshly extracted teeth (single and multirooted) formed the hard tissue study sample. They were cleansed of blood and stains using hydrogen peroxide. All teeth were then measured under stereomicroscope for:

A) Cervico-occlusal (CO) dimension

B) Buccolingual (BL) or Labiolingual (LL) and Mesiodistal (MD) dimension of crown: maximum width of crown and at cemento-enamel junction (CEJ)

C) BL and MD dimension of root at two points corresponding to thirds of root length.

An access cavity was prepared at CEJ and 10% formalin was injected to fix the pulp and immersed in the same solution for 24 hrs. (Figure 1) Nail enamel paint was applied to the teeth just to avoid undue staining of teeth by ink, red ink was injected at CEJ (methylene blue can be used as an alternative dye) and were dipped into the ink for 1 day.

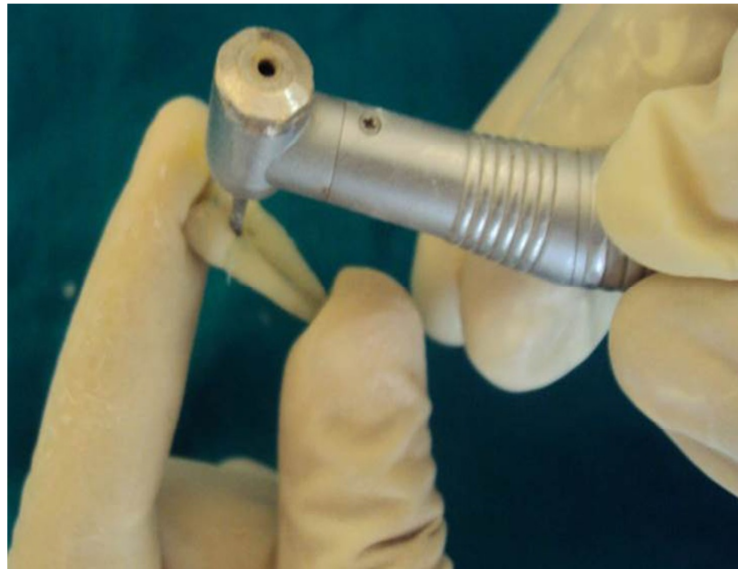


Figure 1: Showing Access Cavity Preparation at CEJ

The access preparation at CEJ was then sealed with glass ionomer cement (GIC) to prevent leaching of ink and to avoid penetration of decalcifying agent. After this, nail paint is scraped off the teeth with the bard parker (BP) blade, Teeth were then placed in 5% HNO₃ (Nitric acid) for 6-8 days for decalcification, then kept under running tap water for removal of acid for 30 minutes followed by natural dehydration in

sunlight till they become dry. Teeth were placed in methylsalicylate (Vatanpour M and Javidi M 2007, Omer OE et al 2004) for clearing, until they become transparent. Disposable plastic tea cups (Vidya M et al 2009) were cut into small pieces (1x1cm approximately), added to jar containing xylene, mixed properly until they form a smooth, homogenous embalming paste (Figure 2).



Figure 2: Showing Teeth Specimens Dipped in Embalming Paste

Teeth were then dipped in paste for about 24 hrs so that the paste can impregnate well then removed and allow to dry

naturally for 2-3 hrs. Resulting specimen were dry and non-sticky showing dyed pulp canal morphology (Figure 3A and 3B).

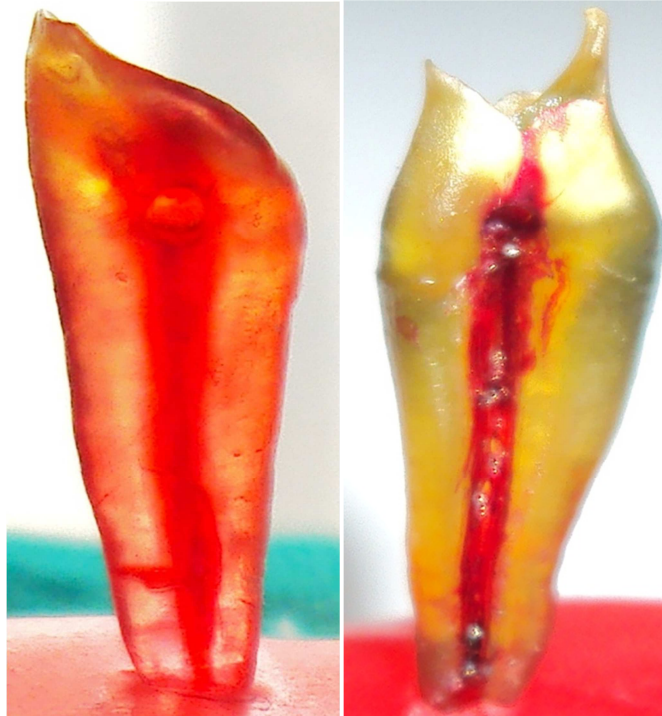

Figure 3A and 3B: Showing Teeth Specimens with Dyed Pulp Canal Morphology

Tooth measurements were noted after decalcification, clearing and plastination

process and were later compared (Table 1).

Table 1: Depicts Shrinkage of Teeth Specimen

Hard Tissue (Average)	After Decalcification	After Clearing	After Plastination
In crown	3% CO 3% MD 0.5% LL	3.5% CO 4% MD 1% LL	No Change
In root	2% MD 2% LL	3% MD 3% LL	No Change

Soft Tissue Plastination:

Ten formalin fixed soft tissue specimens (5 specimen of <5mm in size and 5 specimen of >5mm in size) were taken, followed by dehydration, firstly in 60% alcohol for 1 day followed by absolute alcohol for next 1 day after which the specimen was placed in acetone (clearing agent) for 1 hour. For plastination embalming paste was prepared

similar to that used for teeth and the specimens was dipped in that for 24-36 hrs after which the specimens was removed and were allowed to dry naturally for 2-3 hours. (Vidya M et al 2009) The resulting specimens were dry, non-sticky and easy to handle. (Figure 4A and 4B) Measurement of soft tissue were done after fixation and plastination process and compared. (Table 2)

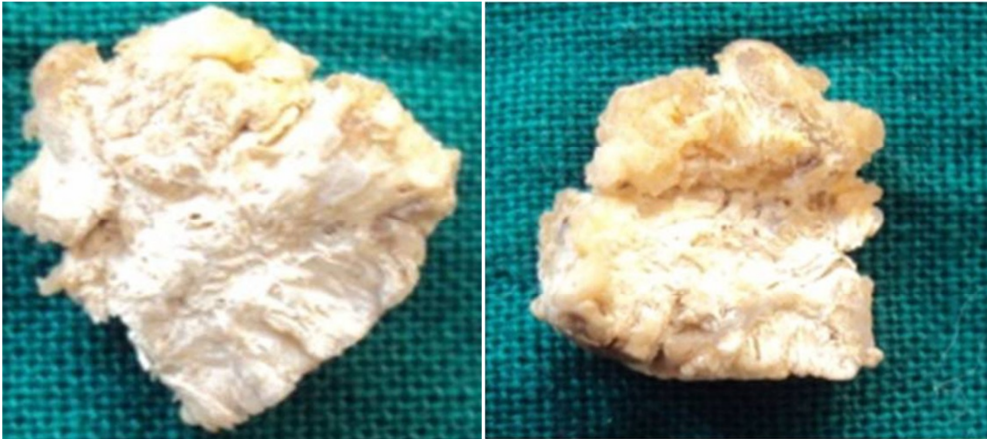


Figure 4A and 4B: Showing Plastinated Soft Tissue Specimens

Table 2: Showing Shrinkage in Soft Tissue Specimen

Soft tissue (average)	Actual (mm)	After fixation (mm)	After plastination (mm)
Size (for tissues <5mm)	4.6	4.2	4
(for tissues >5mm)	5.8	5.1	4.8
Colour	Whitish	Yellowish	Whitish
Consistency	Soft	Soft- firm	Firm-hard

Results and Discussion

The dimensional changes noted for teeth were similar in single and multirouted teeth with maximum shrinkage noted in the crown portion in comparison to the root. Shrinkage was noted following both the procedures of decalcification and clearing. The procedure of plastination resulted in no appreciable change in dimension. This is in contrast to soft tissue specimen where the procedure of plastination also resulted in shrinkage. Change in colour and consistency was also noticed in soft tissue specimens.

Notwithstanding the problem of shrinkage, plastination offers several advantages for study of root canal morphology in being less expensive, offers 3D view, better contrast, less expensive and more acceptable for teaching purposes. To the best of our knowledge, this is the pioneer study utilizing plastination of cleared teeth specimens as a novel way of demonstrating root canal configuration.

We have also experienced that soft tissue plastination have numerous benefits over

conventional museum techniques such as life like appearance, non- exposure to formalin, durability, stability and easy handling for teaching and maintenance free which is in accordance with von Hagens G (1987) and Latorre R. M (2007). Since in the present study we have used disposable tea cups as an alternative to conventional resin, it has tremendously reduced the cost of the technique as in the study by Vidya M et al (2009).

Conclusion

Plastination is a beautiful admixture of science and art aimed for educational purpose to both the dental students and for the patient education. Plastination in combination with clearing technique can satisfactorily demonstrate pulpal morphology of teeth. The advantage it offers makes it an ideal tool for the population based study of root canal morphology and for microleakage studies allowing three dimensional evaluations. The technique can be used adequately for conservation of routine museum specimens and also for preservation of autopsy specimens for forensic purpose.

References

Al-Zuhair, A. G. H., Butt, M. M. & Amonoo-Kuofi, H. S. (1995). 'Plastination-A Modern Technique Supplementing the Teaching of Anatomy,' *Biomed Res*, 6, 231-233.

Aufdemorte, T. B., Bickley, H. C., Krauskopf, D. R. & Townsend, F. M. (1985). "An Epoxy Resin and Silicone Impregnation Technique for the Preservation of Oral Pathology Teaching Specimens," *Oral Surgery, Oral Medicine, Oral Pathology*, 59(1) 74-6.

Grondin, G., Grondin, G. G. & Talbot, B. G. (1994). "A Study of Criteria Permitting the Use of Plastinated Specimens for Light and Electron Microscopy," *Biotechnic & Histochemistry*, 69(4) 219-234.

Latorre, R. M., Garcia-Sanz, M. P., Moreno, M. et al. (2007). "How Useful is Plastination in Learning Anatomy?," *Journal of Veterinary Medical Education*, 34, 172-6.

Omer, O. E., Al Shalabi, R. M., Jennings, M., Glennon, J. & Claffey, N. M. (2004). "A Comparison between Clearing and Radiographic Techniques in the Study of Root Canal Anatomy of Maxillary First and Second Molars," *International Endodontic Journal*, 37, 291-296.

Pashaei, S. (2010). "A Brief Review on the History, Methods and Applications of Plastination," *International Journal of Morphology*, 28(4), 1075-1079.

Ravi, S. B. & Bhat, V. M. (2011). "Plastination: A Novel, Innovative Teaching Adjunct in Oral Pathology," *Journal of Oral and Maxillofacial Pathology*, 15, 133-137.

Saeed, M., Rufai, A. A. & Elsayed, S. E. (2001). "Mummification to Plastination," *Saudi Medical Journal*, 22(11), 956-959.

Vatanpour, M. & Javidi, M. (2007). "Evaluation of Different Clearing Techniques: An Auxiliary Method for Studying Root Canal Anatomy," *The Journal of Islamic Dental Association of Iran (JIDA)*, 19(1), 28-33.

Vidya, M., Shetty, N., Karkera, B. V., Hemanth, M. & Shakil, M. (2009). "Plastination: An Attempt for Oral Specimen," *Indian Journal of Forensic Medicine and Toxicology*, 3(3), 39-40.

von Hagens, G. (1979). "Impregnation of Soft Biological Specimens with Thermosetting Resins and Elastomers," *The Anatomical Record*, 194(2), 247-255.

von Hagens, G., Tiedemann, K. & Kriz, W. (1987). "The Current Potential of Plastination," *Anatomy and Embryology (Berl)*, 175(4), 411-21.