



Case Report

Tuberculousbalanitis: An Unusual Complication of BCG Treatment

Ioannis Efthimiou, Panagiotis Thanasas and Kostadinos Skrepetis

Department of Urology, General Hospital of Kalamata, Greece

Correspondence should be addressed to: Ioannis Efthimiou; efthimiou_ioannis@hotmail.com

Received 10 February 2013; Accepted 25 February 2013; Published 23 April 2013

Academic Editor: Willem J. Oosterlinck

Copyright © 2013 Ioannis Efthimiou, Panagiotis Thanasas and Kostadinos Skrepetis. Distributed under Creative Commons CC-BY 3.0

Abstract

Immunotherapy with Bacillus Calmette-Guérin is widely used for treatment of non-muscle invasive urothelial cancer. Complications associated with Bacillus Calmette-Guérin treatment are common and sometime serious. An unusual case of a tuberculousbalanitis associated with intravesical Bacillus Calmette-Guérin therapy and a review of the literature is presented. Differential diagnosis of this rare complication is difficult and requires a high index of suspicion. Its clinical recognition is essential for early start of antituberculous treatment.

Keywords: Bacillus-Calmette-Guerin, balanitis, bladder cancer.

Introduction

Intravesical Bacillus-Calmette-Guerin (BCG) is the treatment of choice for high risk of progression and optional treatment at intermediate or high risk of recurrence and intermediate risk of progression non-muscle invasive bladder carcinoma (Babjuk, 2012). BCG toxicity is a major issue not only in induction but also in maintenance therapy. Herein we present a case report of an unusual complication of tuberculousbalanitis after BCG treatment.

Case Report

A 61-year-old man with a two year history of T1GIII primary bladder carcinoma and after the last intravesical instillation of BCG during his maintenance course was presented to our department with low grade fever and painful penis. Clinical exam revealed erythematous and tender glans

penis with multiple white and yellow papules and bilateral inguinal lymphadenopathy (figure 1).

Chest X-ray, WBCs and liver enzymes were normal. Due to high index of suspicion for tuberculousbalanitis we proceed to biopsy of the lesions. Histology of penile lesions showed intense granulomatous inflammation with central necrosis and Langhans type giant cells (figure 2) so the diagnosis of penile tuberculosis was confirmed. The patient due to lymphadenopathy was treated with four drug antituberculous therapy (isoniazid, rifampicin, ethambutol, and pyrazinamide in standard daily doses along with pyridoxine for 6 months with discontinuation of pyrazinamide after 2 months). He made an uneventful recovery with complete resolution of penile lesions and lymphadenopathy after 6 months.

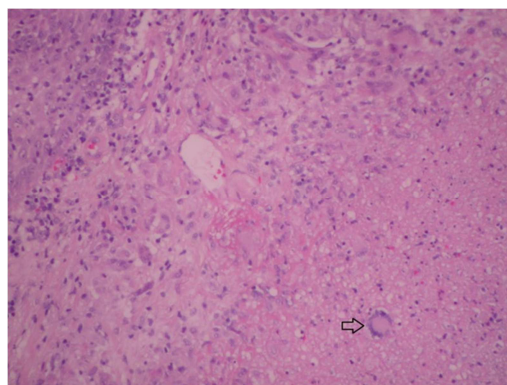


Figure 2. Granulomatous Inflammation with Central Necrosis and Langhans Type Giant Cells (Open Arrow)

Discussion

Penile tuberculosis is a rare complication of BCG therapy. Only 12 cases have been described in the literature (Lestre, 2011). A standardized terminology does not exist, and authors use various terms such as granulomatous balanoposthitis, BCG balanitis, BCG infection of penis etc (Yusuke 2006, Michelet 2008, French 2001). Traumatic catheterization and phimosis are considered risk factors for this complication (Yusuke 2006). However in most cases like in our case there is not any obvious predisposing factor. Typical appearance consists of infiltrated erythematous plaque with yellow papules and central necrosis occasionally associated with inguinal lymphadenopathy (Michelet 2008, French 2001). The diagnosis is based on history, clinical exam and histological findings (Michelet 2008). Histological appearances of these changes typically show epithelioid granuloma with central necroses and giant cells of Langhans type.

Identification of *M. bovis* by traditional methods (Ziehl-Neelsen stain and culture) has been stated to be problematic (Kuresi 2006, French 2001). Talbot et al (1997) has shown that multiplex polymerase chain reaction (PCR) is more effective and specific than conventional methods in BCG detection and may overcome this drawback.

The rarity of this local-regional complication makes a standardized treatment schedule more difficult. In a recent review by Lestre et al (2011) the

duration of treatment has varied between 3-12 months, as well as the number of antitubercular agents used. The treatment scheme recommended for other genitourinary complications with local-regional granulomatous inflammation consists of isoniazid and rifampicine for 3 to 6 months and interruption of BCG therapy. The association of ethambutol is usually reserved for situations with hepatic, pulmonary, renal and skeletal involvement (Rischmann, 2000).

Conclusion

The clinician has to be aware of this rare complication in order to start early therapy with antitubercular agents. Complete resolution of the lesions is the usual outcome.

References

- Babjuck, M., Oosterlink, W., Sylvester, R., Kaasinen, E., Bohle, A., Palou, M. & Roupret, M. (2012). 'Guidelines on Non-Muscle Invasive Bladder Cancer,' *EUA Guidelines*, 1-15.
- French, C. G., Hickey, L. & Bell, D. G. (2001). "Caseating Granulomas on the Glans Penis as a Complication of Bacille Calmette-Guérin Intravesical Therapy," *Rev Urol*, 3(1) 36-8.
- Kureshi, F., Kalaaji, A. N., Halvorson, L., Pittelkow, M. R. & Davis, M. D. P. (2006). "Cutaneous Complications of Intravesical Treatments for Bladder Cancer: Granulomatous Inflammation of the Penis

Following BCG Therapy and Penile Gangrene Following Mitomycin Therapy," *J Am Acad Dermatol*, 55 (2) 328-31.

Lestre, S. I. A., Gameiro, C. D., João, A. & Lopes, M. J. P. (2011). "Granulomas of the Penis: A Rare Complication of Intravesical Therapy with Bacillus Calmette-Guerin," *An Bras Dermatol*, 86 (4) 759-62.

Michelet, N., Spenatto, N., Viraben, R., Cunha, J.- F., Mazet, J. , Trechot, P. , Barbauda, A., & Schmutz, J.- L. (2008). "BCG Infection of the Glans Penis after Intravesical BCG Therapy," *Ann Dermatol Venereol*, 135 (6-7) 479-83.

Rischmann, P., Desgrandchamps, F., Malavaud, B. & Chopin, D. K. (2000). "BCG Intravesical Instillations: Recommendations for Side Effects Management," *Eur Urol*, 37 (Suppl 1)33-6.

Talbot, E. A., Williams, D. L. & Frothingham, R. (1997). "PCR Identification of Mycobacterium Bovis BCG," *J Clin Microbiol*, 35 (3) 566-9.

Yusuke, H., Yoshinori, H., Kenichi, M. & Akio, H. (2006). "Granulomatous Balanoposthitis after Intravesical Bacillus-Calmette-Guerin Instillation Therapy," *Int J Urol*, 13 (10) 1361-3.