



IBIMA
Publishing
mobile

International Journal of Case Reports in Medicine

Vol. 2013 (2013), Article ID 180161, 26 minipages.

DOI:10.5171/2013.180161

www.ibimapublishing.com

Copyright © 2013 Madhusudhan, Shatriah Ismail, Raja Azmi, Adil Hussein and Surini Yusoff. Distributed under Creative Commons CC-BY 3.0

Case Report

Rare Eye Findings in a Case of Sotos Syndrome

Authors

Madhusudhan, Shatriah Ismail, Raja Azmi and Adil Hussein

Department of Ophthalmology, School of Medical Sciences, Universiti Sains
Malaysia, Health Campus, Kelantan, Malaysia

Surini Yusoff

Department of Paediatrics, School of Medical Sciences, Universiti Sains
Malaysia, Health Campus, Kelantan, Malaysia

Received 19 March 2013; Accepted 22 April 2013; Published 24 July
2013

Academic Editor: Cristina Muccioli

Cite this Article as: Madhusudhan, Shatriah Ismail, Raja Azmi, Adil Hussein and Surini Yusoff (2013), "Rare Eye Findings in a Case of Sotos Syndrome," International Journal of Case Reports in Medicine, Vol. 2013 (2013), Article ID 180161, DOI: 10.5171/2013. 180161

Abstract

Objective: To report uncommon eye findings in a case of Soto's Syndrome.

Method: Case report

Results: A 10-year-old girl with underlying Soto syndrome under multidisciplinary care presented with a history of bilateral, painless and progressive blurring of vision for 1 year. On examination, she had accelerated linear growth, dysmorphic facies, macrodolichocephaly, hypertelorism and cognitive impairment. Anterior segment examination revealed bilateral anterior polar cataract and bilateral keratoconus.

Conclusion: What this case highlights is that in addition to the classic features of Soto's syndrome, we found two rare ocular associations in this patient; -_namely, polar cataract and keratoconus. These new additions to the constellation of ocular manifestations of Sotos syndrome serve as a reminder that an ophthalmological evaluation should be a part of the basic workup of children with Sotos syndrome.

Keywords: Sotos syndrome, macrodolichocephaly; anterior polar cataract; keratoconus.

Introduction

Soto's syndrome as first described in 1964 by Soto et al. (1965). This syndrome is described by accelerated linear growth during early childhood and is associated with craniofacial and physical abnormalities, which may include macrodolichocephaly, scoliosis, and enamel hypoplasia (Inokuchiet al. 2001; Tatton-Brown and Rahman 2004; Baujat and Cormier-Daire 2007; Nalini and Biswas 2008). The cause of Soto's syndrome remains unknown, but most often, it occurs sporadically, though occasional cases with autosomal dominant inheritance have been reported (Winship 1985)

Ocular manifestations of Soto's syndrome that have been published before include megalocornea, iris hypoplasia,

cataracts, megalophthalmos, strabismus, nystagmus, and retinal dystrophy (Michael T et al. 2000; Koenekoop et al. 1995). Various rare ophthalmological associations have been reported in the Western literature, and these include unilateral glaucoma, optic disc pallor, and retinal atrophy (Winship 1985; Michael T et al 2000). We are unaware of previous reports of this finding and could find no reference to it, and to our best knowledge;-, this is the first reported keratoconus and anterior polar cataract case in patient with Soto's syndrome.

Case Report

A 10 year-old girl with recurrent fits and a known case of global developmental delay presented with a bilateral whitish reflex

noted by parents for the past one year. She is a known case of Soto's syndrome under multidisciplinary care for the last 8 years.

Birth history revealed prematurity at 32 weeks with a birth weight of 2.5kg by emergency caesarian section due to pre-eclampsia. Birth length was between the 90th and the 97th percentile. Initial presentation to ophthalmology clinic at 2 years of age revealed no gross eye abnormality, and the bone age was estimated to be 3 years old. Regarding the anthropometric measurements, hand and feet length was between the 90th and the 97th percentile at 10 years;_ meanwhile, the head circumference was more than the 95th percentile at 5 years of age. There was no family history of consanguinity, mental deficiency, gigantism, or neurofibromatosis. She had delayed developmental milestones with poor scholastic performance.

General examination revealed typical dysmorphic facies, prognathism, macrocephaly with tall narrow skull, flat nasal bridge, hypertelorism, apparent divergent squint, low set ears, and frontal bossing (Figure 1).

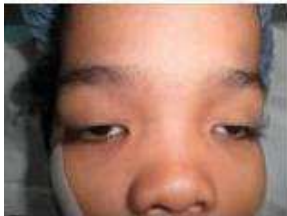

Figure 1: Hypertelorism, Frontal Bossing, and Flat Nasal Bridge.

The patient is able to walk but shows myriad of unpurposeful movement and history of frequent falls. Motor system revealed normal tone and power while reflexes were sluggish. Her mental capability was subnormal with associated poor hearing, and the speech was limited to mumbling sounds. Anterior segment examination revealed bilateral eye with dense anterior polar cataract (Figure 2).

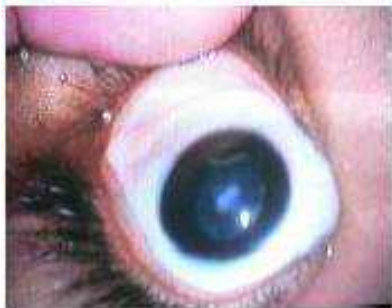

Figure 2: Polar Cataract in the Patient's Right Eye.

The dimensions of cornea were normal, but topographically keratoconus was present (Figure 3).

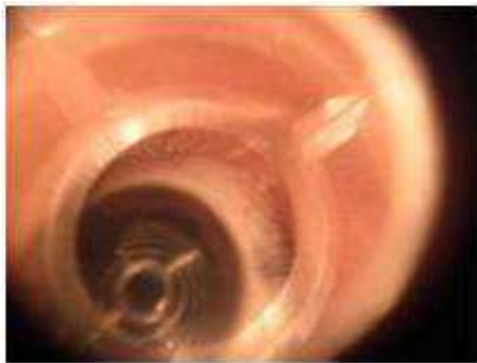


Figure 3: Distorted Mires of a Placido Disc, Suggestive of Keratoconus.

There was an evidence of Vogt striae in the right eye but none in the left. There was no anterior segment dysgenesis seen and angles were open gonioscopically. Fundoscopy revealed healthy optic disc with cup-disc ratio of 0.5 with a normal macula, and there was no abnormal retinal pigmentary changes observed. Cyclo-refraction postoperatively was noted as RE+2.00/-4.75 x 180 and LE +2.50/-3.50 x 160. K-reading showed 47.73 diopters in the right eye, but the left showed 46.00 diopters. (Figure 4). MRI brain showed enlargement of lateral ventricles and no evidence of hydrocephalus. (Figure 5). The pituitary gland was normal. An electroencephalogram also revealed abnormality with highly recurrent spike, poly-spike, and sharp waves. There was no raised T4 and other laboratory investigations were essentially normal. Our patient has undergone uneventful bilateral lens aspiration with intraocular lens implantation. Her visual acuity

has improved from 6/60 to 6/9 in both eyes, with N6 and residual astigmatism.

Discussion

Soto's syndrome also known as cerebral gigantism is a rare disorder of growth and development with characteristic facial gestalt, non-progressive neurologic disorder, and normal endocrine function (Nalini A 2008). Approximately, 1 in 5,000 or 0.02% of 4,400 people in the United States have Soto's syndrome which includes reported cases and undiagnosed cases. From our MEDLINE search, the exact prevalence still remains doubtful. It is a non-hormone mediated accelerated growth disorder, which mimics pituitary gigantism, but with no neuro endocrine dysfunction (Hook EB 1967; Nalini A 2008). Large birth

size with marked linear growth in the first few years of life, advanced bone age, and developmental delay are major diagnostic features in the syndrome- (Cole TR et al 1994). Our patient had typical clinical features with additional associations.

Many published articles have reported cataracts, and interestingly nuclear and cortical cataracts have been described but not polar cataract. Yeh et al. (1978) has described cortical cataracts as early as 1978, and Koenekoop et al. (1995) described nuclear cataracts in 1995-(Michael T et al 2000).

In a study performed on a large population from several colleges and schools of optometry and various clinics of optometrists and ophthalmologists, it was found that moderate-to-high refractive error, nystagmus, and strabismus were commonly associated

with Soto's syndrome (Maino DM et al 1994). Our patient, in addition, had the rare association of keratoconus.

The patho-physiology is not well understood, although it is attributed to disordered collagen and elastin synthesis, and shares a common pathway with various syndromes like Beckwith-Wiedemann, Klippel-Feil, Trenauney, and Weavers syndromes (Douglas et al. 2003; Nalini and Biswas, 2008). The four major diagnostic criteria were established in 1994 by Cole and Hughes (1994) based on the systematic assessment of 41 typical cases: overgrowth with advanced bone age macrocephaly, characteristic facial appearance, and learning difficulties.

(Geneviève Baujat 2007; Cole TR 1994). These clinical criteria remained the cornerstone for the diagnosis of Soto's until 2002.

Discovery of a mutant gene Nuclear SET Domain 1 (*NSD1*) is currently accepted as the cause of this disorder (Douglas et al. 2003 and 2005). Tatton-Brown (2004) analysed clinical features of a large series of more than 200 Soto's syndrome cases with proven abnormalities in *NSD1* and also reported possible link with toxæmia in pregnancy which was evident in our patient's history (Geneviève Baujat 2007; Opitz et al 1998). Unfortunately, no genetic karyo typing was performed on our patient.

Our report provides additional evidence of other rare ophthalmological association with Soto's Syndrome. Even though this is a single case presentation, it is important to highlight to the managing ophthalmologists that keratoconus and polar cataract could possibly be rare ocular features of this syndrome. This condition definitely warrants an early detection and careful

monitoring. Appropriate treatment should be instituted to restore their best visual acuity.

Conclusion

Although relatively few descriptions of ocular findings are found in the existing literature, our report provides additional evidence that these patients can develop treatable ocular problems (Michael T et al 2000). These patients should be examined routinely to allow for early detection and treatment of potential ocular problems; -keratoconus and cataract. This ultimately would be invaluable in the prevention of amblyopia.

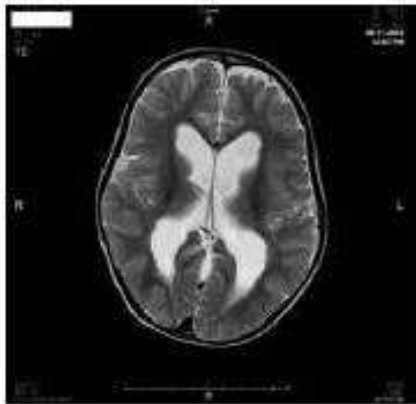

Figure 5: Ventriculomegaly on MRI

References

Baujat, G. & Cormier-Daire, V. (2007). "Sotos Syndrome," *Orphanet Journal of Rare Diseases*, 2, 36.

Cole, T. R. & Hughes, H. E. (1994). "Sotos Syndrome: A Study of the Diagnostic Criteria and Natural History," *Journal of Medical Genetics*, 31(1), 20-32.

Douglas, J., Hanks, S., Temple, I. K., Davies, S., Murray, A., Upadhyaya, M., Tomkins, S., Hughes, H. E., Cole, T. R. & Rahman, N. (2003). "NSD1 Mutations are the Major Cause of Sotos Syndrome and Occur in Some Cases of Weaver Syndrome but are Rare in Other Overgrowth Phenotypes," *The American Journal of Human Genetics*, 72(1), 132-43.

Douglas, J., Tatton-Brown, K., Coleman, K., Guerrero, S., Berg, J., Cole, T. R., Fitzpatrick, D., Gillerot, Y., Hughes, H. E., Pilz, D., Raymond, F. L., Temple, I. K., Irrthum, A., Schouten, J. P. & Rahman, N. (2005). "Partial NSD1 Deletions Cause 5% of Sotos Syndrome and are Readily Identifiable by Multiplex Ligation Dependent Probe Amplification," *Journal of Medical Genetics*. 2005 Sep;42(9):e56.

Hook, E. B. & Reynolds, J. W. (1967). "Cerebral Gigantism: Endocrinological and Clinical Observations Of Six Patients Including a Congenital Giant, Concordant Monozygotic Twins, and a Child Who Achieved Adult Gigantic Size," *The Journal of Pediatrics*, 70(6), 900-14.

Inokuchi, M., Nomura, J., Mtsumura, Y., Sekida, M. & Tagawa, T. (2001). "Sotos Syndrome with Enamel Hypoplasia: A Case Report," *Journal of Clinical Pediatric Dentistry*, 25(4), 313-316.

Koenekoop, R. K., Rosenbaum, K. N. & Traboulsi, E. I. (1995). "Ocular Findings in a Family with Sotos Syndrome (Cerebral Gigantism)," *American Journal of Ophthalmology*, 119(5), 657-8.

Maino, D. M., Kofman, J., Flynn, M. F. & Lai, L. (1994). "Ocular Manifestations of Sotos Syndrome," *Journal of the American Optometric Association*, 65(5), 339-46.

Nalini, A. & Biswas, A. (2008). "Sotos Syndrome: An Interesting Disorder with Gigantism," *Annals of Indian Acadademy of Neurology*, 11(3), 190-2.

Opitz, J. M., Weaver, D. W. & Reynolds, J. F., Jr. (1998). "The Syndromes of Sotos and Weaver: Reports and Review," *American Journal of Medical Genetics*, 79(4), 294-304.

Sotos, J. F., Dodge, P. R., Muirhead, D., Crawford, J. D. & Talbot, N. B. (1964). "Cerebral Gigantism in Childhood. A Syndrome of Excessively Rapid Growth and Acromegalic Features and a Nonprogressive Neurologic Disorder," *The New England Journal of Medicine*, 271, 109-16.

Tatton-Brown, K. & Rahman, N. (2004). "Clinical Features of NSD1-Positive Sotos Syndrome," *Clinical Dysmorphology*, 13(4), 199-204.

Winship, I. M. (1985). "Sotos Syndrome--Autosomal Dominant Inheritance Substantiated," *Clinical Genetics*, 28(3), 243-6.

Yen, M. T., Gedde, S. J. & Flynn, J. T. (2000). "Unilateral Glaucoma in Sotos Syndrome (Cerebral Gigantism)," *American Journal of Ophthalmology*, 130(6), 851-853.