



IBIMA
Publishing
mobile

International Journal of Case Reports in Medicine

Vol. 2013 (2013), Article ID 410335, 20 minipages.

DOI:10.5171/2013.410335

www.ibimapublishing.com

Copyright © 2013 Christopher E. Fundakowski, Jennifer R. Chapman and Zoukaa Sargi. Distributed under Creative Commons CC-BY 3.0

Case Report

Lipogranuloma of the Head and Neck

Authors

Christopher E. Fundakowski and Zoukaa Sargi

Department of Otolaryngology – Head and Neck Surgery, University of Miami –
Miller School of Medicine, Miami, FL, USA

Jennifer R. Chapman

Department of Pathology, University of Miami – Miller School of Medicine,
Miami, FL, USA

Received 28 January 2013; Accepted 13 March 2013; Published 23 April
2013

Academic Editor: Savaş Yakan

Cite this Article as: Christopher E. Fundakowski, Jennifer R. Chapman and Zoukaa Sargi (2013), "Lipogranuloma of the Head and Neck," International Journal of Veterinary Medicine: Research & Reports, Vol. 2013 (2013), Article ID 410335, DOI: 10.5171/2013.410335

Abstract

Objective: To report a rare case of lipogranuloma of the head & neck.

Case Report: We present a 33-year old female patient with a 2-month history of left neck mass refractory to antibiotic therapy. Laboratory workup and fine needle aspiration biopsy was non-diagnostic. Excisional biopsy revealed histologic evidence of a granulomatous soft tissue reaction consistent with lipogranuloma. Lipogranuloma is a very rare finding in the head and neck which typically manifests clinically with painless palpable lymphadenopathy. Two mechanisms have been described for the etiology of lipogranulomas: (1) an exogenous foreign body reaction to either a lipid or oil-like substance, and

the more rare (2) endogenous degeneration secondary to an allergic/inflammatory mechanism as a result of severe heat/cold and/or trauma. Given the patient's history of motor vehicle accident 3 months prior with concurrent neck strain injury, the etiology of lipogranuloma in this case is likely due to endogenous lipid degeneration.

Conclusion: This case reports the rare clinical finding of a patient with lipogranuloma likely secondary to endogenous inflammatory lipid degeneration.

Keywords: Lipogranuloma, head, neck, surgery.

Introduction

Lipogranuloma is a granulomatous inflammatory soft tissue reaction which consists of lipid deposition and/or a material which contains an oil-like substance. Lipogranuloma commonly manifests clinically as palpable lymphadenopathy and subcutaneous nodules. Two mechanisms have been proposed for the development of lipogranuloma: a foreign-body reaction to a lipid/oil-like substance, and secondary to endogenous degeneration of lipids secondary to allergic reaction and/or trauma. Lipogranuloma is well described in the urology literature; but is very rare in the head and neck, particularly in the context of endogenous etiology. A 33 year-old female is presented with lipogranuloma of the neck.

Case History

A 33 year-old female presented with a 2-month history of non-tender left neck mass which had remained stable in size despite a 10 day course of amoxicillin/clavulanic acid. Fine needle aspiration biopsy (FNA) was non-diagnostic (blood only). CT scan confirmed posterior chain lymphadenopathy (largest node, 2.1cm). Past medical/surgical history included silicone breast augmentation (2004), a left axillary node biopsy for lymphadenopathy which revealed reactive lymphadenopathy (2006), and reduction mammoplasty which revealed intraoperative finding of a ruptured right-sided implant (2010). Review of systems was significant for a low-speed motor vehicle accident 3 months prior which resulted in minor neck strain injury which was managed conservatively with outpatient

rehabilitation. The patient had not suffered any recent illness, did not possess fevers or night sweats, did not have severe heat/cold exposure, no weight loss, and no history of illicit drug use. Physical examination revealed a soft mobile non-tender 2 cm mass with no overlying skin changes in the left lower posterior triangle. Comprehensive metabolic panel, lactate dehydrogenase level, and uric acid were noted to be within normal limits. The patient elected for excisional biopsy over repeat FNA.

Final pathology revealed a 2 cm lymph node with centrally located multinucleated giant cells containing endogenous lipid material along with dilated nodal sinuses which contained lipid-laden histiocytes and extracellular lipid material (FIGURE 1 & 2). Oil-red-O staining was positive both within foamy histiocytes and

extracellular spaces, a finding consistent with lipogranuloma. No refractive particles were noted within the specimen, which argued against silicone lymphadenopathy. Lymphoma workup was negative, with no evidence of B cell rearrangement by kappa light chain PCR, nor presence of clonal lymphocyte population.

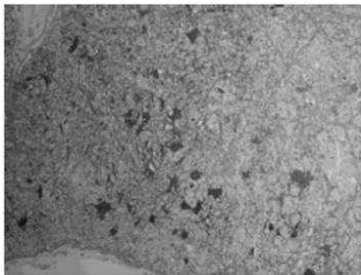


Figure 1. Hematoxylin and Eosin, 4x. Lymph Node with Architectural Effacement Due to Marked Sinusoidal and Subcapsular Dilatation with Resultant Compression of Normal Nodal Follicles and Interfollicular Areas

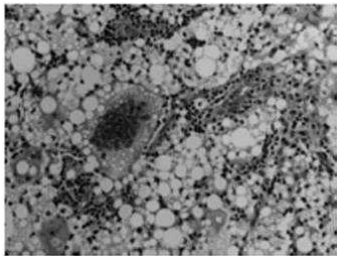


Figure 2. Hematoxylin and Eosin. 40x. Lipogranulomatous Lymphadenopathy. Note the Centrally Located Multinucleated Giant Cell Containing Abundant Endogenous Lipid Material. Surrounding this Giant Cell are Dilated Nodal Sinuses Filled with Lipid-Containing Histiocytes as Well as Abundant Extracellular Lipid Material.

Discussion

Lipogranuloma is a granulomatous soft tissue reaction which involves either lipid or oil deposits and typically manifests clinically as subcutaneous nodules or rubbery lymphadenopathy. While rare, lipogranuloma is most commonly documented in the urologic literature, as the most common site is the genitals of young adults secondary to the injection of foreign materials for penile augmentation, as described by Hohaus (2003). Few reports exist in the literature which describe lipogranuloma of the head and neck. Bassichis (2003) described a lipogranuloma of the nasal sidewall 1 year status-post rhinoplasty thought to be secondary to postoperative nasal packing impregnated with petroleum ointment. Similarly, Guo (2007) reported three cases of eyelid lipogranuloma after endoscopic sinus surgery (all

developed within 1 month postoperatively) in patients who suffered medial orbital wall injury and had subsequent postoperative petroleum-based nasal packing. In all cases, definitive diagnosis and treatment occurred by surgical excision of the lesion in question.

The differential diagnosis for a neck mass is commonly quite broad. When considering the diagnosis of lipogranuloma, it is important to note that the majority of patients will have some element of history which relates to lipid deposition (injection, surgical, traumatic). Though one must also consider the possibility of lymphatic migration, as the original site of deposition may be in a different anatomic location from where the lipogranulomatous lymphadenopathy manifests.

Lipogranuloma may be initially confused for malignancy, and

FNA may be of limited benefit, as noted by Peoc'h (2000), where biopsy not only did not provide a diagnosis, but mimicked lymphoma. Significant axillary lymphadenopathy (silicone lymphadenopathy) has also been noted in the context of patients who have undergone silicone breast augmentation mammoplasty.

The pathophysiology of lipogranuloma has been described via two different mechanisms, exogenous and endogenous. Exogenous etiology occurs secondary to the body's inability to metabolize exogenous oils in the tissue interstitium which subsequently results in a foreign body granulomatous reaction. Endogenous etiology elicits lipid degeneration from an allergic/inflammatory mechanism as a result of severe heat/cold

and/or trauma. Lipogranuloma via endogenous etiology is noted to be a more rare occurrence.

Lipogranulomatous lymphadenopathy specifically refers to the presence of endogenous lipid material within a lymph node. Hausner (1982) described lipogranulomatous lymphadenopathy, where the lipid material is typically present in both the extracellular space as well as within histiocytes, which in turn confers a vacuolated or foamy appearance to the cell. Lipid material is identified histologically based on a characteristic round, empty, droplet appearance with marked variation in size of individual droplets (FIGURE 1 & 2). Special stains for lipid, such as Oil-red-O, can be performed for confirmation.

The main differential diagnosis for this patient with lipogranulomatous lymphadenopathy, particularly in the context of a history of silicone breast augmentation mammoplasty, is silicone lymphadenopathy. After breast implant rupture, migration of silicone gel to draining lymph nodes may occur. Although silicone lymphadenopathy may be associated with chronic granulomatous inflammation, including the presence of multinucleated giant cells, it differs from lipogranulomatous lymphadenopathy in that silicone lymphadenopathy is characterized by the presence of multinucleated foreign body-type giant cells in association with and often containing refractive particles of foreign material. In this case, not only was the ruptured implant on the contralateral side, but no foreign material was identified histologically, thus ruling out silicone lymphadenopathy secondary to implant rupture. As a result,

endogenous etiology for lipogranuloma formation secondary to lipid degeneration is supported given the patient history of neck trauma (motor vehicle accident).

Lipogranulomatous lymphadenopathy is a rare clinical entity, particularly in the head and neck and should be considered in the differential diagnosis of neck mass. Our aim is that this report may be useful for both otolaryngologists and health care practitioners when faced with a neck mass with complex clinical history.

References

Bassichis, B. A. & Thomas, J. R. (2003). "Foreign Body Inclusion Cyst Presenting on the Lateral Nasal Sidewall 1 Year after Rhinoplasty," *Arch Facial Plast Surg*, 5(6):530-532.

Guo, Y., Peng, A., Xie, D., Li, Y., Ren, J., Xiao, M., Fan, S., Yang, X., Wu, W. & Xie, D. (2007). "Diagnosis and Management of Lipogranuloma of the Eyelids from Nasal Endoscopic Surgery," (Article in Chinese), *Lin Chung Er Bi Yan Hou Tou Jing Wai Ke Za Zhi*, 21(8):340-343.

Hausner, R. J., Schoen, F. J., Mendez-Fernandez, M. A., Henly, W. S. & Geis, R. C. (1981). "Migration of Silicone Gel to Axillary Lymph Nodes after Prosthetic Mammoplasty," *Arch Pathol Lab Med*, 105(7):371-372.

Hohaus, K., Bley, B., Köstler, E., Schonlebe, J. & Wollina, U. (2003). "Mineral Oil Granuloma of the Penis," *J Eur Acad Dermatol Venereol*, 17:585-587.

Peoc'h, M., Duprez, D., Grice, G., Fabre-Bocquentin, B., Gressin, R. & Pasquie, B. (2000) "Silicone Lymphadenopathy Mimicking a Lymphoma in a Patient with a Metatarsophalangeal Joint Prosthesis," *J Clin Pathol*, 53(7):549-51.