



Case Report

Spontaneous Intra-Peritoneal Hematoma: An Unusual Complication of Thrombolysis

Ashish Bhalla, Harpreet Kaur, Navneet Sharma and Subhash Varma

Department of Internal Medicine, Post Graduate Institute of Medical Education and Research,
Chandigarh, India

Correspondence should be addressed to: Ashish Bhalla; bhalla.chd@gmail.com

Received 30 January 2013; Accepted 27 March 2013; Published 27 May 2013

Academic Editor: Pedro Beraldo De Andrade

Copyright © 2013 Ashish Bhalla, Harpreet Kaur, Navneet Sharma and Subhash Varma. Distributed under Creative Commons CC-BY 3.0

Abstract

Thrombolytic agents have been used in the emergency department for treatment of acute myocardial infarction and vasoocclusive strokes. Their use has been associated with complications. The most dreaded complication is bleeding following systemic thrombolysis. We document a case of spontaneous intra-peritoneal hematoma following thrombolysis with streptokinase in a patient with acute myocardial infarction, which was managed conservatively.

Keywords: Thrombolysis, Complications, Bleeding, intraperitoneal hematoma.

Introduction

Fibrinolytic drugs are used to degrade thrombi which are either administered systemically or delivered via catheters directly into the substance of the thrombus. Systemic delivery is used for treatment of acute myocardial infarction (AMI) in settings where primary percutaneous coronary interventions are not possible/ available. They are also being used to treat acute ischemic stroke, and massive pulmonary embolism. The goal of therapy is to produce rapid thrombus dissolution, thereby restoring antegrade blood flow. Primary percutaneous coronary intervention is the standard of care but in developing countries thrombolytics are still being used to treat AMI. (Chan WK 1996, Malik JK 2004)

Thrombolytic agents are considered relatively safe, but systemic thrombolysis is not free from complications. (Chan WK 1996, Malik JK 2004) The adverse effects could be minor or major bleeding, cardiac arrhythmias, anaphylactoid reaction or cerebrovascular accident. Hemorrhage is the most dreaded life-threatening complication. There is a small but significant risk of systemic thrombolytic administration. (Malik JK 2004) Intraperitoneal hematoma is unusual complication following thrombolysis. We report one such case here which was managed conservatively.

Case Report

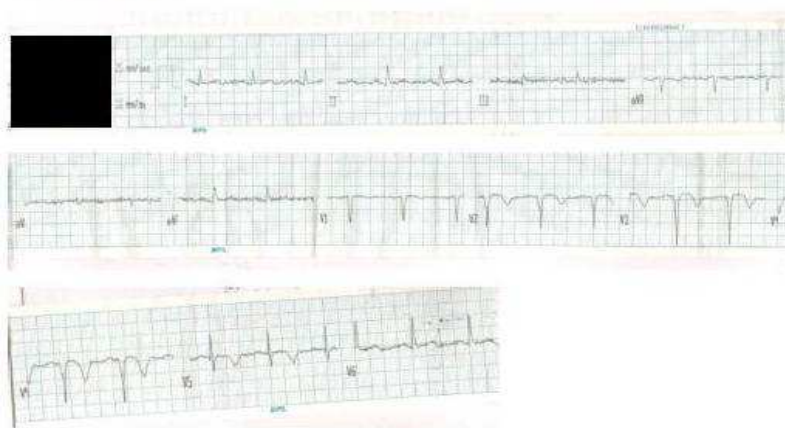
A 52 year old male, a known hypertensive for last 5 years, presented to our emergency with complaints of chest pain since 2 days

two days and abdominal pain for one day prior to admission.

He was apparently well 2 days prior to admission when he complained of chest pain associated with uneasiness. He was taken to local hospital where an ECG was done which showed T-wave inversion in leads V₂ -V₅ . (Fig 1) The diagnosis of Acute MI was made and he was thrombolysed with Streptokinase 1.5MU, given intravenous over 30 minutes. His chest pain was significantly relieved post thrombolysis. He started complaining of severe lower abdominal pain the next day.

There was no fever and no bowel complaints. There was no bleeding from any site. There was no history of prior fall or blunt trauma abdomen. Since the pain was not relieved by analgesics, therefore he was referred to our emergency. On examination, he was haemodynamically stable except for tachycardia (heart rate 110/minute). His systemic examination revealed mild tenderness in the lower abdomen. There was no lump palpable and there was no evidence of any free fluid or air in the abdomen. The mucous membranes and skin did not reveal any bleeding manifestation.

1a: EKG done out side



1b: EKG done on arrival in the emergency

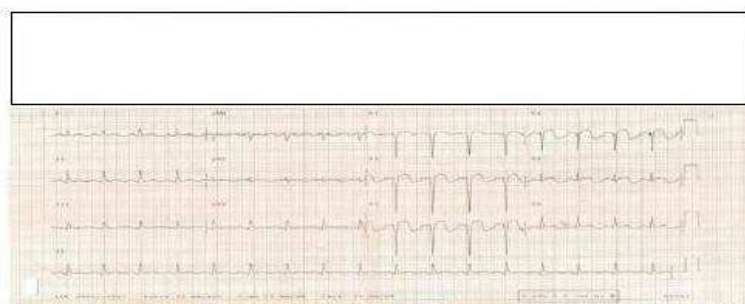


Fig 1: EKG Showing Qs Pattern in Lead V1-V4 with ST Segment Elevation. T Inversion is Seen in V1-V5

A possibility of hematoma or an intraabdominal abscess was kept. Under sonographic guidance, needle aspiration

from the collection was done and haemorrhagic fluid was obtained. Since the fluid was rich in polymorphs and the sugars

were low, a contrast enhanced tomogram (CECT) of abdomen was done. It revealed a large hematoma in the right pelvis measuring

around 17 x 11 cm. There was no evidence of any contrast extravasation, vascular disruption or aneurysm. (Fig 2)

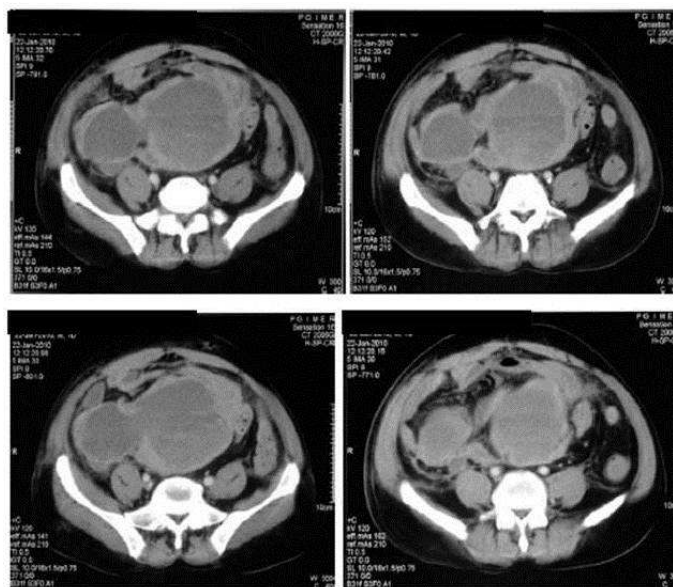


Fig 2: CECT Abdomen Showing Intraperitoneal Hematoma

On workup, there was no evidence of anemia or thrombocytopenia. Bleeding time and clotting time was within normal range. His renal functions were mildly deranged (Sr creatinine 1.5mg/dl) however the patient was non-oliguric. The repeat ECG showed Q waves with ST elevation and T-wave inversion in leads $V_2 - V_5$. An ultrasonography of the abdomen, done by an experienced sonologist, revealed a heterogenous hypoechoic collection measuring 13.5 x 8.3 cm with evidence of internal septae, echoes and debris. A possibility of hematoma or an intraabdominal abscess was kept. Under sonographic guidance, needle aspiration from the collection was done and haemorrhagic fluid was obtained. Since the fluid was rich in polymorphs and the sugars were low, a contrast enhanced tomogram (CECT) of abdomen was done. It revealed a large hematoma in the right pelvis measuring around 17 x 11 cm. There was no evidence of

any contrast extravasation, vascular disruption or aneurysm.

The patient was managed conservatively. Antiplatelets and anticoagulants were withheld. Betablockers, ace inhibitors and statins were continued. Surgical opinion was sought and conservative management was advised. The patient was followed up by serial sonograms, serial haemoglobin estimations and bleeding time estimations. There was a gradual decrease in the size of the hematoma (sonographically demonstrated). The haemoglobin remained stable and there was no increase in bleeding/clotting time. The patient improved clinically during the hospital stay. He was discharged after 10 days of admission with 7 x 5 cm residual hematoma still persisting. On further follow up, gradual decrease in the size of hematoma was noted over next 6 weeks. The patient was lost to follow up after that.

Discussion

Streptokinase is the most commonly used thrombolytic in resource constraint settings because of its cost. It is considered relatively safe but hemorrhagic complications are not uncommon. Most of these hemorrhagic complications are minor. (Chan WK 1996) Risk factors for hemorrhagic complications include increasing age, elevated pulse pressure, uncontrolled hypertension, recent stroke or surgery, presence of a bleeding diathesis, and severe congestive heart failure. (Awadh N et al 1994)

Bleeding following systemic thrombolysis usually stems from a vascular access site, mucosal (oral, gastrointestinal, urinary, etc.) or skin/soft tissue. Bleeding episodes tend to be more serious in patients requiring invasive procedures (Chan WK 1996).

In one prospective study, Chan, et al assessed the complications arising from use thrombolytic agents in Chinese patients with acute myocardial infarction. They observed that only 13.9% (19/136) patients had complications with the most common complication being bleeding. The commonest site of bleeding was gums followed by intracranial hemorrhage, right groin hematoma, hematuria and hemoptysis in one patient each (Chan WK 1996).

In an Indian study by Malik et al., 29/102 patients thrombolysed using Streptokinase developed complications. Bleeding was the most common adverse effect seen in 10.7% (11patients). The most common bleeding sites were venepuncture site and GI bleed. Spontaneous hematoma on the medial side of thigh was reported in one patient only. (Malik JK 2004).

Intraperitoneal hemorrhage may result from systemic diseases, such as bleeding diathesis but blunt / penetrating abdominal trauma is the most important cause.(Willis SM 1984) Spontaneous intraperitoneal hemorrhage may result from several incidentally discovered etiologies, including rupture of a vascular

neoplasm, hemorrhagic cyst, or ectopic pregnancy; perforation of a duodenal ulcer or other gastrointestinal pathologies; and inflammatory erosive processes (Willis SM 1984). In our patient these possibilities were ruled out clinically as well as radiologically.

Thrombolytic induced spontaneous intraperitoneal hematomas are rarely reported. Occasional cases of subcapsular hepatic hematomas have been reported with thrombolytics like streptokinase and r-tpa (Jimenez AG et al. 1997). Kenan et al reported a case of an 80year old female developing abdominal pain and distention of increasing intensity following thrombolysis. Abdominal computed tomography demonstrated a huge intraperitoneal hematoma (Kenan Yalta et al 2007), as seen in our patient.

Management of streptokinase induced bleeds involves application of direct pressure to minor sites of bleeds and discontinuation of the lytic agent and antiplatelet drugs. In cases of major bleeds with drop of hemoglobin or hypotension, volume replacement by blood transfusion is indicated. Cryoprecipitates may be helpful in unresponsive bleeds. Plasma infusion is usually not required if the levels of fibrinogen are 100 mg/dl or more. Aminocaproic acid, Aprotinin and Tranexamic acid are the available antifibrinolytic agents commonly used to reverse the bleeding. (Akhtar TM 1992). Aprotinin has been specifically used to control bleeding in patients requiring rescue CABG after receiving streptokinase. The recommended dose administered after streptokinase is 2 million KIU before bypass, with an additional 1-2 million KIU added to the pump prime and a continuous infusion of 0.5 million KIU per hour during surgery (Akhtar TM 1992).

In our patient, the hematoma itself could have resulted in localized compression and contained the bleeding. We had discontinued antiplatelets and anticoagulants and watched for further bleeding by monitoring

haemoglobin and abdominal distention. Since these conservative measures contained the bleeding, other supportive measures like blood transfusion, antifibrinolytics and cryoprecipitates were not needed.

Surgical drainage of streptokinase induced hematomas is usually not required, as was the case in our patient. Spontaneous resolution is a rule rather than exception. In some cases of intracranial hematomas, successful outcomes have been reported with timely neurosurgical evacuation. (Al-Khuwalia TS 2005)

Conclusions

Generalized fibrinolytic state attained after institution a non specific thrombolytic can predispose a patient to bleeding complications. Mild non life threatening bleeds and superficial bleeds can be managed conservatively but patient could develop massive bleeding in anybody compartment. Spontaneous intra peritoneal hematoma is an unusual complication following thrombolysis with streptokinase. One should carefully observe patients following thrombolysis, intervention may not always be possible in acute stage. Conservative management will usually suffice in such patients.

References

- Akhtar, T. M., Goodchild, C. S. & Boylan, M. K. G. (1992). "Reversal of Streptokinase Induced Bleeding with Aprotinin for Emergency Cardiac Surgery," *Anaesthesia* ,47:226-228.
- Al-Khuwalia, T. S., Wani, B. A., Daywood, H. A. & Khan, M. A. (2005). "Successful Outcome after Evacuation of Intracranial Hematoma Following Thrombolysis in Acute Myocardial Infarction," *Saudi Med J*;vol 26(1):130-132.
- Awadh, N. Ronco, J. J., Bernstein, V., Gilks, B. & Wilcox, P. (1994). "Spontaneous Pulmonary Hemorrhage after Thrombolytic Therapy for Acute Myocardial Infarction," *Chest*;106:1622-4.
- Chan, W. K., Chiu, A. & Yui, C. S. (1996). 'Prevalence of Various Complications of Thrombolytic Therapy in Patients with Acute Myocardial Infarction: Experience in a Local Regional Hospital,' *J HK Coll cardiol*; vol 4:77-80.
- Jimenez, A. G., Mao, M. C., Moan, D. F., Ferreiro, S. O., Gutierrez, M. G., Marini, M. et al. (1997). "Hepatic Bleeding and Hemorrhagic Shock Following Thrombolytic Therapy in Patients With Acute Myocardial Infarction," *Chest*;111;1787.
- Malik, J. K. & Khan, G. Q. (2004). "Adverse Effect Profile of Streptokinase Therapy in Patients with Acute Myocardial Infarction: A Prospective Study," *JK Practitioner*;11(2):106-109.
- Willis, S. M. & Bailey, S. R. (1984). "Streptokinase-Induced Subcapsular Hematoma of the Liver," *Arch Intern Med*; 144: 2084-2085
- Yalta, K., Birhan, M., Karadaş, F. & Gümüş, C. (2007). "Spontaneous Massive Intraperitoneal Hematoma Accompanied by Acute Severe Anemia after Low-Dose Thrombolytic Therapy," *Türk Kardiyol Dern Arş*; 35:370-372.