



**IBIMA**  
Publishing  
*mobile*

# ***International Journal of Case Reports in Medicine***

*Vol. 2013 (2013), Article ID 439839, 18 minipages.*

*DOI:10.5171/2013.439839*

*www.ibimapublishing.com*

Copyright © 2013 Amit Kumar C Jain and S. Viswanath.  
Distributed under Creative Commons CC-BY 3.0

*Case Report*

**Large Bowel Perforation in an Acute Inguinal Hernia  
Resulting from Blunt Abdominal Trauma**

**Authors**

**Amit Kumar C Jain and S. Viswanath**

Department of Surgery, St John's Medical College, Sarjapur road, Karnataka,  
India

Received 10 July 2013; Accepted 9 September 2013; Published 30  
November 2013

Academic Editor: Faruk Çoşkun

**Cite this Article as:** Amit Kumar C Jain and S. Viswanath (2013), "Large Bowel Perforation in an Acute Inguinal Hernia Resulting from Blunt Abdominal Trauma," International Journal of Case Reports in Medicine, Vol. 2013 (2013), Article ID 439839, DOI: 10.5171/2013.439839

## **Abstract**

Traumatic abdominal hernia is a very rare condition with less than 70 reported cases, in spite of an increase in the incidence of trauma. Often, the trauma to the abdomen results in damage to solid or to the hollow viscus. The trauma causing TAWH can be due to high energy or low energy impact. We report a very rare condition wherein there was a blunt injury to the abdomen that resulted in the acute inguinal hernia with perforated sigmoid colon, small bowel and part of urinary bladder being its contents. To our knowledge, this is the first such case being documented by us.

**Keywords:** Trauma, Inguinal hernia, Perforation.

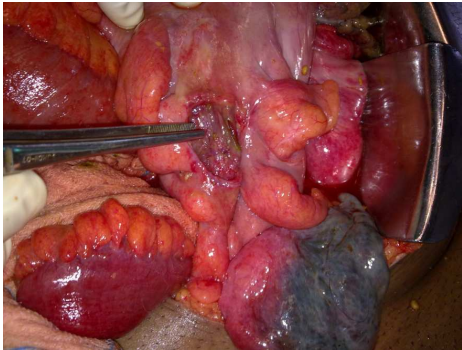
## **Introduction**

Blunt abdominal trauma (BTA) may cause either a crushing or a shearing effect resulting in damage to the hollow viscus or solid viscera (Biswas 2010, Lawal 2012). Around 5% of patients with blunt trauma have injury to mesentery and intestine (Uppot 2000).

Acute traumatic abdominal hernias are considered to be very rare with less than 70 cases reported in literature till 2005 (Ogundiran 2012). Bowel perforation in the patients with hernias occur either from blunt trauma to abdomen or from trauma directly to inguinal hernia (Uppot 2000). We report for the first time the occurrence of a sigmoid perforation with its herniation into the inguinal canal occurring at the same time.

## **Case Report**

A 45 year old male patient presented to our emergency department with history of trauma to the abdomen that occurred in the morning. A barrel had fallen on him. Immediately after the trauma, the patient developed severe abdominal pain and an inguino-scrotal swelling on the left side. There was no history of vomiting, fever or previous inguinal swelling.



**Figure 1: Showing the Large Sigmoid Perforation (Pointed by the Forceps) and Gangrenous Lateral Fold of the Urinary Bladder (Arrow)**



On examination, patient was found to have dyspnoea and tachypnoea with a respiratory rate of 44 /min. His pulse was 130/min and blood pressure was 130/70mmHg.

On abdominal examination, patient had tenderness all over the abdomen with guarding and rigidity. There was a left inguinoscrotal swelling which was tender and irreducible.

His laboratory investigation showed a haemoglobin – 16.7g%. Total count – 3790mm<sup>3</sup>, Platelets – 1.97 lacs/mm<sup>3</sup>, INR- 1.3. His renal functions, serum electrolytes and liver functions were found to be within normal limits. His ABG showed metabolic acidosis.

Ultrasound abdomen showed moderate free fluid in abdomen. Scrotal ultrasound revealed a left inguinoscrotal hernia with bowel loops as its content and a heteroechoic area in scrotum suggestive of fluid collections.

CT scan abdomen was done which showed a left inguinoscrotal hernia with poor mucosal enhancement of sigmoid colon. There was air, fluid and extensive fat stranding within the hernia sac, to consider the possibility of bowel ischaemia. There was pneumoperitoneum, free fluid in abdomen and omental thickening. There was also bilateral pleural effusion and basal atelectasis.

Patient underwent exploratory laparotomy which revealed a gross faecal peritonitis with herniation of bowels in left deep

inguinal ring. The contents were pulled back in abdomen which included perforated sigmoid colon with faeces in the sac, small bowel and a gangrenous lateral fold of urinary bladder.

He underwent sigmoid colostomy, excision of gangrenous fold and peritoneal lavage. He underwent a relook laparotomy and peritoneal lavage 6 days later as he had high fever spikes.

Patient recovered postoperatively and he underwent colostomy reversal 4 months later.

## **Discussion**

TAWH was first reported by Selby in 1906 (Hardcastle 2005). TAWH is defined as herniation of the viscera through the

abdominal wall within the context of disrupted muscle and fascia layers but with intact skin, where there is distinct history of trauma preceding the occurrence of the hernia (Hardcastle 2005). Bowel injury due to BTA in an inguinal hernia is very rare in literature (Lyutskanov 2007). The TAWH occurs due to a blunt force that leads to shearing of muscle and fascia. This shearing is thought to occur at anatomic weak points such as the inguinal region or the lower abdomen lateral to the rectus muscle (Bemmel 2011).

In a preexisting inguinal hernia, a direct trauma to the hernia causes compression of the incoming and outgoing loops of bowels, forming a sealed loop. Raised intraluminal pressure leads to perforation of the bowel within sac (Lyutskanov 2007). A

pressure of 150-260mmHg is required to rupture the intestinal loops (Uppot 2000).

Traumatic abdominal hernia falls into 3 categories (Wood 1988) namely,

- a) Small lower quadrant defects and inguinal hernias, typically the result of blunt trauma with bicycle handlebars. This is the most common traumatic abdominal hernia. It is due to low energy impact.
- b) Large abdominal wall defects sustained in motor vehicle accidents. This is second most common

- c) Intraabdominal herniation through rents in the peritoneum.  
This is very rare.

The treatment of traumatic abdominal hernia consist of surgical exploration with the closure of the defect (Bemmel 2011). The repair of the defect should be preferably done with non absorbable suture material and mesh should be avoided to prevent septic complications (Hardcastle 2005). Presence of peritonitis requires primary surgical intervention through laparotomy.

## **Conclusion**

Traumatic abdominal hernia is an extremely rare condition. It is of 3 types. It can occur either due to low energy or high energy

impact. Early recognition and treatment is essential in reducing morbidity and mortality. Associated abdominal visceral injury invariably requires an exploratory laparotomy/laparoscopy for further management. Placement of mesh after repairing the hernia is usually avoided.

## References

Bemmel, A. J. M., Marle, A. G. J., Schlejen, P. M. & Schmitz, R. F. (2011). "Handle Bar Hernia: A Case Report and Literature Review of Traumatic Abdominal Wall Hernia in Children," *Hernia*, 15(4), 439-442.

Biswas, S., Vedanayagam, M., Hipkins, G. & Leather, A. (2010). "Acute Direct Inguinal Hernia Resulting from Blunt Abdominal Trauma: Case Report," *World Journal of Emergency Surgery*, 5, 16.

Hardcastle, T. C., Coetzee, G. N. & Wasserman, L. (2005). "Evisceration from Blunt Trauma in Adults: An Unusual Injury Pattern: 3 Cases and a Literature Review," *Scandinavian Journal of Trauma, Resuscitation and Emergency Medicine*, 13, 234-235.

Hardcastle, T. C., Toit, D. F. D., Malherbe, C., Coetzee, G. N., Hoogerboord, M. & Warren, B. L. (2005). "Traumatic Abdominal Wall Hernia - Four Cases and a Review of the Literature," *South African Journal of Surgery*, 43(2), 41-43.



Lawal, K. & Adamu, A. (2012). "Handle Bar Hernia: A Case Report and Review of Literature," *Archives of International Surgery*, 2, 42-44.

Lyutskanov, V., Kondarev, M., Markov, G. & Kondarev, G. (2007). 'Small Bowel Perforation due to Blunt Abdominal Trauma Associated with Right Inguinal Hernia: Report of a Case,' *The Internet Journal of Surgery*, 13(2), 1-4.

Ogundiran, T. O., Obamuyide, H. A., Adesina, M. A. & Ademola, A. F. (2012). "Case Report of Traumatic Abdominal Wall Hernia Following Blunt Motorcycle Handlebar Injury and Review of Literature," *Nigerian Journal of Clinical Practice*, 15(2), 238-240.

Uppot, R. N., Gheyi, V. K., Gupta, R. & Gould, S. W. (2000). "Intestinal Perforation from Blunt Trauma to a Inguinal Hernia," *American Journal of Roentgenology*, 174(6), 1538.

Wood, R. J., Ney, A. L. & Bubrick, M. P. (1988). "Traumatic Abdominal Hernia: A Case Report and Review of the Literature," *The American Surgeon*, 54(11), 648-651.