



IBIMA
Publishing
mobile

International Journal of Case Reports in Medicine

Vol. 2013 (2013), Article ID 820966, 15 minipages.

DOI:10.5171/2013.820966

www.ibimapublishing.com

Copyright © 2013 Amit Kumar C Jain and Viswanath S.
Distributed under Creative Commons CC-BY 3.0

Case Report

**Acute Intestinal Obstruction Due to Meckel's Diverticulum:
A Case Report**

Authors

Amit Kumar C Jain and Viswanath S

Department of surgery, St. John's Medical College and Hospital, John Nagar,
India

Received 22 April 2013; Accepted 26 May 2013; Published 5 July 2013

Academic Editor: Anette Sundfor Jacobsen

Cite this Article as: Amit Kumar C Jain and Viswanath S (2013), "Acute Intestinal Obstruction Due to Meckel's Diverticulum: A Case Report," International Journal of Case Reports in Medicine, Vol. 2013 (2013), Article ID 820966, DOI: 10.5171/2013.820966

Abstract

Vast majority of Meckel's diverticulum patients are asymptomatic, and they are often detected at laparotomy or laparoscopy. The common complications that can arise are bleeding, obstruction, and inflammation. Obstruction is considered to be the common complication of Meckel's diverticulum in adults though it is seen rarely in clinical practice and it can be due to various mechanisms. This case report presents a rare mechanism of small bowel obstruction secondary to Meckel's diverticulum.

Keywords: Meckel's diverticulum, small bowel, obstruction.

Introduction

There are many etiologies of small bowel obstruction with adhesions, and hernia is being the most common (Jabri 2012). Small bowel obstruction secondary to Meckel's diverticulum as such is rare in a surgical practice. Meckel's diverticulum is the most common congenital anomaly of the gastrointestinal tract (Jabri 2012, Srinivas 2007, and Cartanese 2011). Majority of these patients are asymptomatic (Papaziogas 2007).

Complications due to Meckel's diverticulum include hemorrhage, intestinal obstruction, diverticulitis, Littre's hernia, umbilicus sinus, and tumours (Cartanese 2011 and Papaziogas 2007). Of all these complications, small bowel obstruction is the most common one seen in adults. This case report describes an unusual way of small bowel obstruction due to Meckel's

diverticulum wherein the tip of the Meckel's diverticulum was adherent to the antimesenteric border of ileum, thereby creating a ring through which there was small bowel herniation.

Case Report

A 60-year-old male patient, who was a known case of renal failure on haemodialysis at our institute, presented with history of pain abdomen since 2 days. The pain was colicky in nature and was increasing in severity. It was associated with nausea, vomiting, and obstipation. There was no history of fever, melena, or haematemesis. His pulse was 96/min and blood pressure was 180/110 mmHg. The abdomen was soft, grossly distended with tenderness in epigastrium. There was no palpable mass, and the

per-rectal examination revealed hard stools. His bowel sounds were increased.

Laboratory findings showed haemoglobin 9.7g%, leukocyte count 14,000 cmm, s creatinine 6mg%, and blood urea 75mg%. His Liver function was normal. X-ray abdomen showed dilated small bowel loops with air fluid levels. An ultrasound was done which showed bilateral grade 3 renal parenchymal disease with dilated small bowel loops and sluggish peristalsis and moderate free fluid. Plain CT scan revealed a complete obstruction with a zone of transition at proximal ileum probably a stricture. There is free fluid in abdomen and renal parenchymal disease.

Patient underwent an emergency exploratory laparotomy. At exploration, it was found that the tip of the Meckel's diverticulum was adherent to the antimesenteric border of the proximal ileum forming a ring through which there was herniation of loops of ileum (Figure 1). There was ascites and mesenteric lymphadenopathy. The tip was separated from the ileum. There was small serosal tear which was sutured. Meckel's diverticulectomy was performed. Patient's postoperative period was uneventful. The histopathology confirmed Meckel's diverticulum without any gastric or pancreatic tissue.

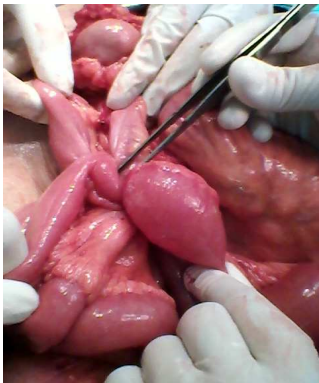


Figure 1: The Adhesion of the Meckel's Diverticulum to Proximal Ileum with Ileal Loop Entrapment

Discussion

Small bowel obstruction accounts for 20% of all surgical emergencies (Thakor 2007). As such, Meckel's diverticulum is a rare cause of small bowel obstruction. There are various mechanisms causing intestinal obstruction like intussusceptions, volvulus, Littre's hernia, enterolith, stricture, entangling of a loop of bowel around a fibrous cord, neoplasm, and so forth (Srinivas 2007, Papaziogas 20007, and Sharma 2008).

In this case, the obstruction was because of adhesion of tip of Meckel's diverticulum to proximal ileum resulting in trapping of ileal loops in it. The literature shows that there are only very few case reports with similar pattern of obstruction (Devanaboyana 2008). Most of these cases are diagnosed only during surgery.

The overall lifetime risk of development of complications from Meckel's diverticulum is said to be around 4% (Srinivas 2007), with one-third of cases resulting in small bowel obstruction (Papaziogas 2007).

The surgical treatment options are diverticulectomy or ileal resection (Cartanese 2011 and Papaziogas 2007). The mortality from surgery for complicated Meckel's diverticulum is 1.5% (Cartanese 2011). A few centres do perform laparoscopic resection of Meckel's diverticulum (Cartanese 2011).

Conclusion

Meckel's diverticulum is an uncommon etiological cause of small bowel obstruction. There are various mechanisms for its causation. The diagnosis is often made at surgery, just like the way we made during surgery. The overall mortality from surgery of Meckel's diverticulum is very low. This case report presents a rare mechanism of small bowel obstruction due to Meckel's diverticulum.

References

Al Jabri, K. A. & El Sherbini, A. (2012). "Small Bowel Obstruction due to Meckel's Diverticulum: A Case Report," *Oman Medical Journal*, 27 (1), 1-3.

Cartanese, C., Pettiti, T., Marinelli, E., et al. (2011). "Intestinal Obstruction Caused by Torsed Gangrenous Meckel's Diverticulum Encircling Terminal Ileum," *World Journal Gastrointestinal Surgery*, 3(7), 106-109.

Devanaboyana, G., Ranger, D. S. & Shami, S. (2008). "Meckel's Diverticulum Causing Mechanical Small Bowel Obstruction," *Canadian Journal of Surgery*, 51(2), 156.

Papaziogas, B., Makris, I., Tsiaousisp, et al. (2007). "An Unusual Case of Intestinal Obstruction Caused by a Meckel's Diverticulum," *Aristotle University Medical Journal*, 34(1), 55-59.

Sharma, R. K. & Jain, V. K. (2008). "Emergency Surgery for Meckel's Diverticulum," *World Journal of Emergency Surgery*, 3, 27.

Srinivas, G. N. S. & Cullen, P. (2007). "Intestinal Obstruction due to Meckel's Diverticulum: A Rare Presentation," *Acta Chirurgica Belgica*, 107, 64-66.

Thakar, A. S., Liao, S. S. & Riordan, D. C. (2007). "Acute Small Bowel Obstruction as a Result of a Meckel's Diverticulum Encircling the Terminal Ileum: A Case Report," *Journal of Medical Case Reports*, 1, 8.