



Case Report

Non-Recurrent Laryngeal Nerve and Aberrant Vasculature

Tsu-Hui (Hubert) Low¹ and Anthony Clifford²

¹Sydney Head & Neck Cancer Institute and Department of Otolaryngology, Royal Prince Alfred Hospital, Camperdown, Australia

²Sydney Head & Neck Cancer Institute, Royal Prince Alfred Hospital, Camperdown, Australia

Correspondence should be addressed to: Tsu-Hui (Hubert) Low; hubelow@yahoo.com

Received 7 May 2013; Accepted 23 May 2013; Published 24 June 2013

Academic Editor: Jonathan W. Serpell

Copyright © 2013 Tsu-Hui (Hubert) Low and Anthony Clifford. Distributed under Creative Commons CC-BY 3.0

Abstract

Background: The incidence of non-recurrent laryngeal (RLN) nerve is around 0.5%. Injury to the nerve results in significant morbidity.

Methods and Results: A case of a 63-year old lady with a non-RLN and an aberrant subclavian artery was described. A successful thyroidectomy was performed with subcapsular dissection and identification of the RLN medially. Embryogenesis and anatomical variations of the non-RLN were reviewed, and their clinical importance was discussed.

Conclusions: It is important for surgeons who regularly perform thyroidectomies to be aware of the association between aberrant subclavian artery and the presence of non-RLN.

Keywords: Thyroidectomy; recurrent laryngeal nerve; aberrant subclavian artery.

Introduction

The Case

A healthy 63 year old lady presented with obstructive symptoms from a multinodular

goitre. Preoperative CT of the neck confirmed a retrosternal multinodular goitre (Figure 1), as well as an aberrant right subclavian artery (Figure 2).

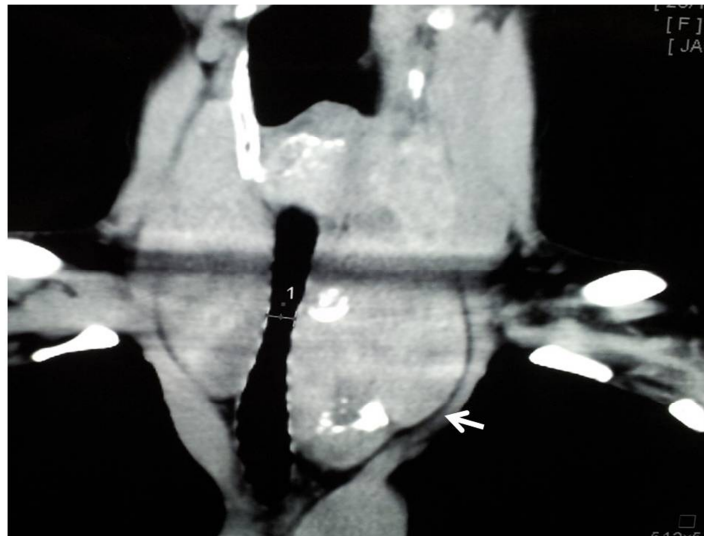


Figure 1: Coronal CT Showing the Retrosternal Extension of Multinodular Goitre (Arrow).

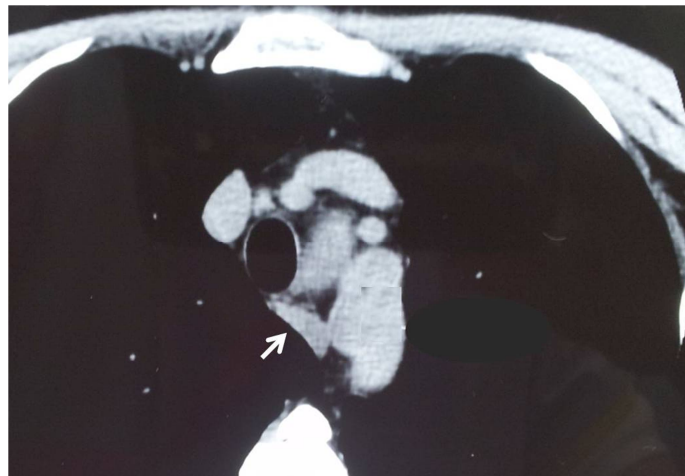


Figure 2: Axial CT Showing an Aberrant Right Subclavian Artery (Arrow).

A careful subcapsular total thyroidectomy was performed after division of strap muscles. A right non-recurrent laryngeal nerve (RLN) was identified medially, near the cricothyroid muscle, and traced laterally. The nerve was noted to emerge deep to the carotid artery (Figure 3). Four parathyroid glands were identified and preserved. On postoperative day one, the

PTH was 5.2pmol/L with corrected calcium of 2.28 mmol/L. The recovery was uneventful and the voice was normal. The patient was discharged on day 2 after drain removal. Histopathology confirmed benign multinodular goitre measuring 103x68x52mm and 98x36x52mm for both left and right lobes, respectively.

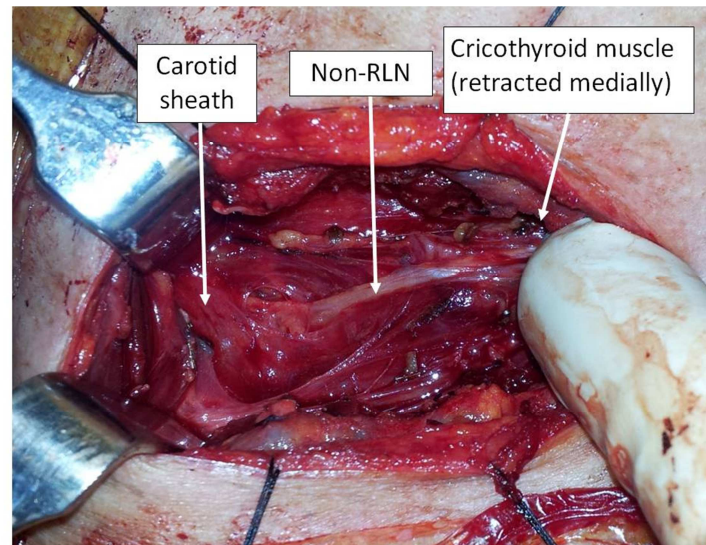


Figure 3: Intraoperative Photo Showing the Right Non-Recurrent Laryngeal Nerve, Arising Deep to the Carotid Sheath and Coursing toward the Cricothyroid Muscle.

Discussions

Injury to the RLN from thyroidectomy occurs in about 1% of cases, resulting in significant morbidity. The incidence of non-RLN is reported to be 0.54%; this leads to increased risk of inadvertent injury to the nerve in inexperienced hand (Toniato et al., 2004).

This case highlights the fact that when an aberrant vasculature is noted amongst patients undergoing thyroid surgeries, the surgeon needs to be prepared for the possibility of a non-RLN.

Embryologically, right subclavian artery is formed from the 4th arch structure and RLN is formed from the 6th arch structure. During embryogenesis, the heart descends, dragging the 6th arch structure (including RLN). Anomaly of subclavian artery on the right side leads to the failure of the right RLN to descend (Defechereux et al., 2000 and Abboud and Aouad, 2004). Right subclavian artery in these cases often courses behind the oesophagus, the incidence of which is reported to be around 0.5%–2% (Campbell et al., 1991, Casal et al., 2010, and Toniato et al., 2004). It is also important to note that a small proportion

of these patients with retro-oesophageal subclavian artery (with normal-sized thyroid gland) will complain of symptoms of dysphagia (Cannon, 1999 and Casal et al., 2010). Therefore, clinicians will also need to counsel their patients appropriately in regard to the possibility of persistent dysphagic symptom amongst patients with concurrent retro-oesophageal subclavian artery and multinodular goitre.

Toniato et al. (2004) reviewed their series of 6000 thyroidectomies (where 31 have non-RLN). They reported three variations of the non-RLN; the non-RLN could be closely related to the superior thyroid vessels (type 1), parallel and over the trunk of the inferior thyroid artery (type 2a), or parallel but under or between the branches of the inferior thyroid artery (type 2b) as seen in Figure 4 (adapted from Nakatani et al., 1998, Toniato et al., 2004, and Abboud and Aouad, 2004). This schematic drawing also highlights the point that despite all the known variations, the position of the non-RLN is constant in its medial position, close to the cricothyroid muscle; therefore, routine identification of the RLN medially where the anatomy is more constant could minimize the risk of injuring the non-RLN during dissection.

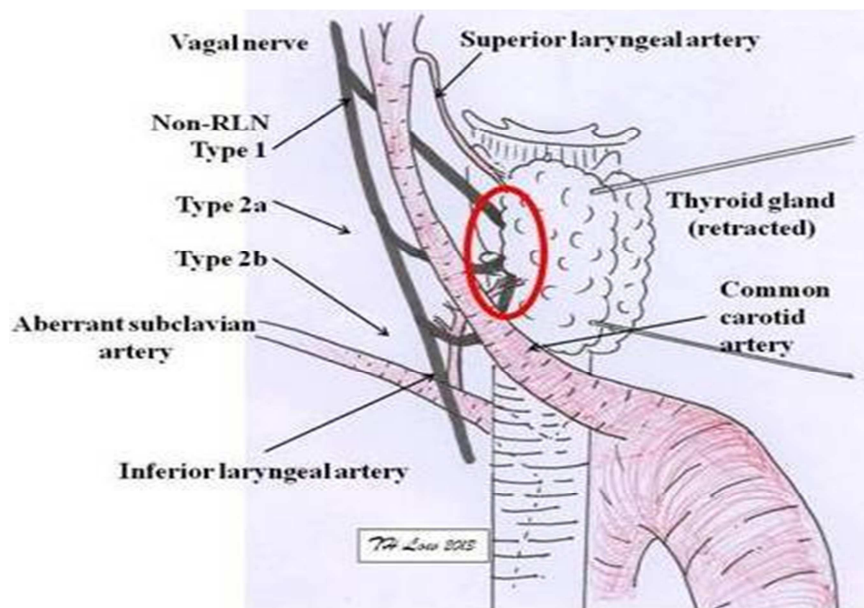


Figure 4: Schematic Diagram of the Three Variations of Non-RLN. The Course of the Non-RLN is Variable Lateral to the Thyroid Gland but Remains Constant at Its Medial Position (Red Circle).

In conclusion, surgeons and trainees who regularly perform thyroidectomy should understand the association between vascular anomaly and non-RLN. By adhering to the technique of subcapsular dissection and identification of the RLN close to the cricothyroid muscle, the risk of injuring the non-RLN could be minimized.

References

- Aboud, B. & Aouad, R. (2004). "Non-Recurrent Inferior Laryngeal Nerve in Thyroid Surgery: Report of Three Cases and Review of the Literature," *Journal of Laryngology and Otology*, 118, 139-42.
- Campbell, P. R., Serpell, J. W. & Young, E. (1991). "Non-Recurrent Laryngeal Nerves. The Role of Digital Subtraction Angiography to Identify Subjects," *Australian and New Zealand Journal of Surgery*, 61, 358-9.
- Cannon, C. R. (1999). "The Anomaly of Nonrecurrent Laryngeal Nerve: Identification and Management," *Otolaryngology -- Head and Neck Surgery* 120, 769-71.
- Casal, D., Peças, A., Sousa, D. & Rosa-Santos, J. (2010). "A Non-Recurrent Inferior Laryngeal Nerve in a Man Undergoing Thyroidectomy: A Case Report," *Journal of Medical Case Reports*, 4, <http://www.jmedicalcasereports.com/content/4/1/386>.
- Defechereux, T., Albert, V., Alexandre, J., Bonnet, P., Hamoir, E. & Meurisse, M. (2000). "The Inferior Non Recurrent Laryngeal Nerve: A Major Surgical Risk during Thyroidectomy," *Acta Chir Belg*, 100, 62-7.
- Nakatani, T., Tanaka, S. & Mizukami, S. (1998). "Anomalous Triad of a Left-Sided Inferior Vena Cava, a Retroesophageal Right Subclavian Artery, and Bilateral Superficial Brachial Arteries in One Individual," *Clinical Anatomy*, 11, 112-7.
- Toniato, A., Mazzarotto, R., Piotto, A., Bernante, P., Pagetta, C. & Pelizzo, M. (2004). "Identification of the Nonrecurrent Laryngeal Nerve during Thyroid Surgery: 20-Year Experience," *World Journal of Surgery*, 28, 659-61.