



IBIMA
Publishing
mobile

Plastic Surgery: An International Journal

Vol. 2013 (2013), Article ID 821692, 30 minipages.

DOI:10.5171/2013.821692

www.ibimapublishing.com

Copyright © 2013 Mamatha Hosapatna, Hemalatha Bangera, Naveen Kumar, Suhani Sumalatha and Nitya. This is an open access article distributed under the Creative Commons Attribution License unported 3.0, which permits unrestricted use, distribution, and reproduction in any medium, provided that original work is properly cited.

Morphological Variations in Lumbricals of Hand – A Cadaveric Study

Authors

**Mamatha Hosapatna, Hemalatha Bangera,
Suhani Sumalatha and Nitya**

Department of Anatomy, Kasturba Medical College, Manipal, Manipal
University, Manipal. Karnataka, India

Naveen Kumar

Department of Anatomy, Melaka Manipal Medical College (Manipal campus)
Manipal, Manipal University, Manipal. Karnataka, India

Abstract

The hand is a prehensile organ, it is endowed with grasping and precision movements for skilled work and it acts as a chief tactile apparatus. Thus human hand is a revolution in evolution. Indeed the lumbricals of the hand by producing flexion at the metacarpophalangeal joints and extension at the interphalangeal joints helps in writing, stitching and any other forms of precision work. A study was conducted in the department of Anatomy, Kasturba Medical College, Manipal with 30 cadavers of both sexes. The study was carried out to check for the variations in the origin, insertion, innervations and the extension of lumbrical muscle. 93.3% of case showed the normal morphology of lumbricals and remaining showed the variations like bifid first lumbrical, bipennate 2nd lumbrical, absence of 3rd lumbrical,

hypertrophied 1st lumbrical. Anomalous and additional lumbrical muscle can cause carpal tunnel syndrome by compressing the median nerve. Hypertrophy of the lumbricals could compress the radial and ulnar arteries of the fingers, causing chronic sub ischemia. Hence present work is under taken to know the variations in the lumbricals.

Key words: lumbricals, bifid, hypertrophy, bipennate, proximal.

Introduction

The hand is a prehensile organ, it is endowed with grasping and precision movements for skilled work and it acts as a chief tactile apparatus. This is contributed by a higher degree of neuromuscular co-ordination and a larger cortical representation of the hand in the sensory and motor cortices of the brain. Hence, philosophically it may be said that the actions of the lumbricals of the hand are the indices of civilization of a race (Standring, 2005).

Evolution of grasping ability of the human being contributed by lumbricals may be attributed to the ecological context of such skills in the frogs (Adriana et al., 2008). Hence, human hand is a revolution in evolution. Indeed the lumbricals of the hand by producing flexion at the metacarpophalangeal joints and

extension at the inter-phalangeal joints helps in various object manipulating skills like writing, stitching and any other forms of precision work. Lumbricals play a vital role in precision movements of the hand. These are four small muscles of the hand. They are numbered from lateral to medial side. They originate in the palm from the tendons of flexor digitorum profundus, pass distally along the corresponding metacarpophalangeal joint in front of the deep transverse metacarpal ligament. Each muscle forms a narrow tendon and on reaching the dorsal surface of the proximal phalanx joins the margin of the dorsal digital expansion (Soubhagya et al., 2008).

The lumbrical muscles, especially the 1st and 2nd lumbricals, are used as muscle flaps for the coverage of the median nerve and its palmar branches. Hypertrophy of the lumbrical muscles causes

compression of the radial and ulnar collateral arteries, leading to chronic sub-ischemia (Mehta and Gardner, 1961). Hence presence work is undertaken to know the morphological variations in the lumbricals.

Materials and Methods

This study was conducted in the Department of Anatomy, Kasturba Medical College, Manipal with 30 cadavers of both sexes with the age range approximately between 35-65 years. The study was carried out during the routine dissection procedure for undergraduate medical students in the department of anatomy. A longitudinal incision was made from the distal end of the flexor retinaculum, up to the level of the metacarpophalangeal joint of the middle finger. The superficial

fascia, the deep fascia and the flexor retinaculum were dissected and reflected. Then the tendons of flexor digitorum superficialis, flexor digitorum profundus, branches of median nerve and superficial palmar arch were retracted. The lumbrical muscles were carefully observed and isolated. They were then followed to their tendons which pass to the lateral side of the base of each finger and later, the tendons of each of the lumbrical muscles were traced up to their insertions. The study was carried out to check for the variations in the origin, insertion, innervations and the extension of lumbrical muscle.

Result

The detailed profile of patterns of variations in the lumbricals of the hand is shown in Table 1.

Table 1- Showing the Profiles of Different Variations of Lumbricals of the Hand.

Pattern	No. of cases	Percentage of their incidences
Normal Origin	24	93.3%
Proximal Origin	2	6.67%
Bifid 1 st lumbrical	1	3.3%
Bipennate 2 nd Lumbrical	1	3.3%
Absent 3 rd Lumbrical	1	3.3%
Hypertrophied lumbrical	1	3.3%

From the data of our present study, lumbricals with their normal attachments were observed in majority (93.3%) of palms. However, significant variations were also observed in some of the palms such as its proximal origin beneath the flexor retinaculum in 6.67% cases (**Fig 1**).

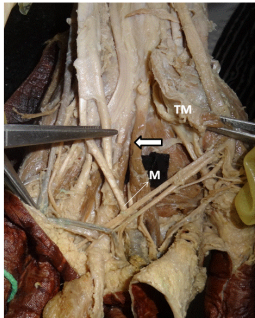


Fig: 1- Dissection of palm showing proximal origin of 2nd lumbrical (thick arrow). M- tendon of flexor digitorum profundus for the middle (M) finger, TM- thenar muscles

Fig: 1- Dissection of Palm Showing Proximal Origin of 2nd Lumbrical from the Tendon of Flexor Digitorum Profundus for the Middle Finger

Bifid 1st lumbrical were seen in 3.3% of cases (**Fig 2**) and equal percentage of cases showed the presence of bipennate 2nd lumbrical arising from lateral two tendons of flexor digitorum profundus muscle (**Fig 3**).

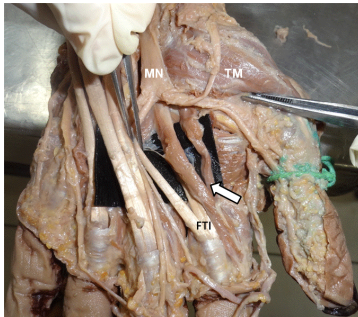


Fig: 2- Dissection of palm showing bifid 1st lumbrical (arrow). MN- median nerve. FTI- Lone flexor tendons of Index finer. TM- thenar muscles

Fig: 2- Dissection of Palm Showing Bifid 1st Lumbrical

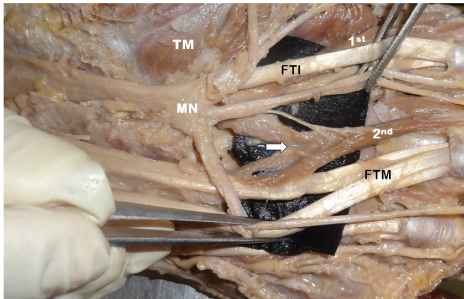


Fig: 3- Dissection of palm showing bipennate 2nd lumbrical (arrow). 1st- First lumbrical , MN- median nerve, TM- thenar muscles. FTI- Flexor tendon of index finger ,2nd – second lumbrical, FTM- Long flexor tendons of middle finger

Fig: 3- Dissection of Palm Showing Bipennate 2nd Lumbrical

In all these cases, their patterns of insertion were normal. In 3.3 % of the cases, there was absences of 3rd lumbrical were noted (**Fig 4**).

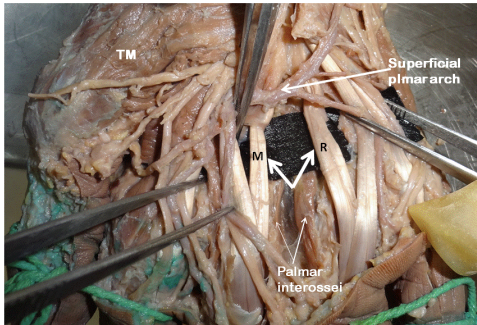


Fig: 4- Dissection of palm showing absence of 3rd lumbrical, which normally arises from contiguous sides of the tendons of flexor digitorum profundus for the middle (M) and ring fingers (R), TM- thenar muscles

Fig: 4- Dissection of Palm Showing Absence of 3rd Lumbrical

With the similar frequency, the hypertrophied first lumbrical were observed with its normal attachments (**Fig 5**).

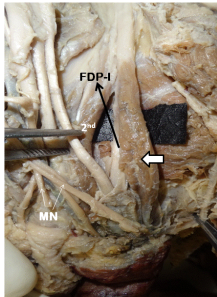


Fig: 5- Dissection of palm showing hypertrophied first lumbrical (thick arrow) originating from tendon on flexor digitorum profundus to index finger (FDP-I). 2nd – second lumbrical, MN- branches of median nerve

Fig: 5- Dissection of Palm Showing Hypertrophied First Lumbrical Originating from Tendon on Flexor Digitorum Profundus to Index Finger

In addition to these, rare variations like presence of additional muscle belly from the tendon of flexor pollicis longus were also observed (**Fig 6**).

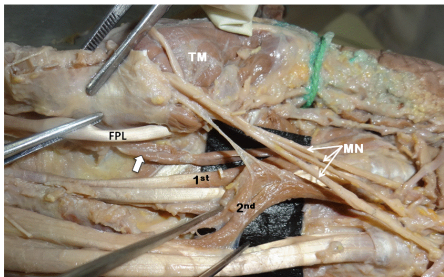


Fig: 6- Dissection of palm showing additional muscle belly (thick arrow) from tendon of flexor pollicis longus (FPL) to 1st lumbrical (1st). MN- branches of median nerve, TM- thenar muscles.
2nd – second lumbrical

Fig: 6- Dissection of Palm Showing Additional Muscle Belly Arising from Tendon of Flexor Pollicis Longus (FPL) for First Lumbrical

The innervations pattern to each variant lumbricals were found to be normal that is first two being supplied by the median nerve and third and fourth being supplied by ulnar nerve. No additional or dual nerve supply has been observed in cases of bifid lumbricals.

Discussion

Lumbricals as a part of the intrinsic musculature is important for its digital movements. They are quite unique as they connect the flexors of the digits to the extensors. Variations in the attachments of the lumbricals are common. In a study which was conducted by Mehta and Gardner (1961), it was noted that the lumbricals had an occasional origin in the forearm or from a metacarpal or from the superficial instead of the deep flexor

tendons and that the third and fourth lumbricals originated from a single tendon instead of two. The presence of an additional muscle belly for the first lumbrical was seen in present case which has a phylogenetical significance and the occurrence of such an anomalous muscle belly may compress the median nerve in carpal tunnel.

Anomalous and additional lumbrical muscle can cause carpal tunnel syndrome by compressing the median nerve (Chaudruc et al., 2000). Similar observation was seen in a study done by Singh et al., (2011) as a bipennate origin of first lumbrical, extending from the distal part of forearm and had split insertion.

A muscle which arose from the anomalous flexor pollicis longus tendon in the region of the metacarpophalangeal joint, passes

across the narrowed first web space joined the lumbrical belly of the index and inserted into extensor hood of that digit. Because of its attachments and action, it was given the name musculus lumbricals pollicis. Additionally, notification of such muscular variants assumes importance in event of surgical intervention (Lister, 1991).

In the present study most of the lumbricals had a normal origin but some showed a proximal anomalous origin beneath the flexor retinaculum. Similar report has been reported by a study done by Siegel et al., (1995) with the incidence of 26.6% and opined that, it may cause compression of median nerve in carpal tunnel. It is also found that in case of carpal tunnel syndrome and in those in which repetitive hand motions were performed, the lumbricals had a significantly larger and proximal origin in the carpal tunnel

which could be the cause of the carpal tunnel syndrome (Joshi et al., 2005).

Hypertrophy of the lumbrical muscles which could cause the compression of radial and ulnar arteries of the fingers likely to cause chronic sub ischemia (Singh et al., 1975).

The lumbricals also shows variations in being unipennate or bipennate. The present study showed the presence of bipennate 2nd lumbrical in 3.3% of the cases. The significance and etiology of such variant lumbrical was not found in literature. If the first lumbrical is bipennate instead of unipennate then two heads usually arise from the flexor digitorum profundus and flexor pollicis longus (Goldberg, 1970).

In the present study, one case showed rare anomaly of absence of third lumbrical. A study done by Braithwaite et al (1948), documented the absence of fourth lumbrical but with no clinical significance for this observation. A study by Kurzumi et al (2002) concluded that evidence of absence of 4th lumbrical was the most frequent absent of the lumbricals.

Conclusion

In the present study, though we observed presence of lumbricals with their normal attachment and morphology in majority of cases, a rare variations like their proximal origin, bi pinnate 2nd lumbricals, absence of 3rd lumbrical and hypertrophied lumbricals were also been encountered. These unusual variations assume wide range of clinical implications. Therefore, clinicians

and hand surgeons should be aware of enormous variations in lumbricals during various surgical procedures of hand. Further, hypertrophied lumbricals can cause compression of the radial and ulnar digital arteries leading to chronic ischemia. Hence, a complete knowledge of possible variations of lumbricals is utmost essential.

References

Braithwaite, F., Channel, G. D., Moore, F. T. & Whillis. J. (1948). 'The Applied Anatomy of the Lumbrical and Interosseous Muscles of the Hand,' *Guy's Hosp. Reports*, 97, 185–95.

Chaudruc, J. M., Florenza, F., Riviere, C. & Arnaud, J. P. (2000). "White Finger and Hypertrophy of the Lumbrical Muscles," *Chir Main*, 19 (4) 232-34.

Goldberg, S. (1970). "The Origin of the Lumbrical Muscles in the Hand of the South African Native," *The Hand*, 2, 168-71.

Joshi, S. D., Joshi, S. S. & Athavale, S. A. (2005). "Lumbrical Muscles and Carpal Tunnel," *J Anat Soc India*, 54(1) 12-15.

Kurzumi, M., Karwai, K., Honma, S. & Kodama, K. (2002). "Anomalous Lumbrical Muscles Arising from the Deep Surface of Flexor Digitorum Superficialis Muscles in Man," *Ann Anat*, 184(4) 387-92.

Lister, G. (1991). "Musculus Lumbricalis Pollicis," *J Hand Surg [Am]*, 16(4) 622-5.

Manzano, A. S., Abdala, V. & Herrel, A. (2008). "Morphology and Function of the Forelimb in Arboreal Frogs: Specializations for Grasping Ability?," *J.Anat*, 213(3) 296-307.

Mehta, H. J. & Gardner, W. U. (1961). "A Study of Lumbrical Muscles in the Human Hand," *Am. J. Anat*, 109, 227-238.

Siegel, D. B., Kuzma, G. & Eakins, D. (1995). "Anatomic Investigation of the Role of Lumbricals Muscle in Carpal Tunnel Syndrome," *J. Hand Surg (Am)*, 20(5) 860-3.

Singh, G., Bay, B. H., Yip, G. W.. C. & Tay, S. (2001). "Lumbrical Muscle with an Additional Origin in the Forearm," *ANZ J Surg*, 71, 301-2.

Singh, J. D., Raju, P. B. & Singh Shamer. (1975). 'Anomalous Insertion of Hand Lumbricals,' *J Anat Soc India*, 24 (3) 122-5.

Soubhagya R Nayak, Ramya Rathan, Rachana Chauhan, Ashwin Krishnamurthy & Latha V Prabhu. (2008). "A Case Report -An Additional Belly of First Lumbrical Muscle," *Cases Journal*, 1(1) 103.

Standring, S. (2005). Gray's Anatomy, 39th Ed. *Edinburgh: Elsevier Churchill Livingstone*, 1021-3.