



Research Article

# Hemiagenesis of the Right Lobe and Isthmus of the Thyroid Presenting as Multinodular Goitre

Sanoop Koshy Zachariah, Praseetha Narayanan, Noble Verghise Mathew  
and Sreejith L Krishnankutty

Medical College, Kolenchery, Cochin, India

Correspondence should be addressed to: Sanoop Koshy Zachariah; skzach@yahoo.com

Received date: 24 October 2013; Accepted date: 9 December 2013; Published date: 28 February 2014

Academic Editor: Marek Ruchala

Copyright © 2014. Sanoop Koshy Zachariah, Praseetha Narayanan, Verghise Mathew, and Sreejith L Krishnankutty. Distributed under Creative Commons CC-BY 3.0

## Abstract

Thyroid hemiagenesis is a rare variant of thyroid dysgenesis in which one lobe of the gland fails to develop. It is considered to be the rarest developmental abnormality of the thyroid gland. Only about 310 cases have been reported till date. Hemiagenesis commonly involves the left lobe and very rarely the right lobe. We present an unusual case of thyroid hemiagenesis of the right lobe and isthmus in a 36 year old female who presented with a multinodular goitre. The clinical features, radiological and operative findings of this unusual case are presented along with a review of literature.

**Keywords:** Thyroid; congenital anomalies, hemiagenesis,

## Introduction

The thyroid gland is the first endocrine gland to start developing in the embryo. Morphological and structural developmental anomalies of the thyroid gland are relatively rare. Thyroid developmental anomalies (TDA) (*excluding biochemical abnormalities*) can be divided into three groups namely agenesis (or athyreosis), dysgenesis, and anomalies due to persistence of the thyroglossal tract (Jain and Pathak, 2010). Thyroid dysgenesis includes thyroid hemiagenesis, thyroid hypoplasia, ectopic, aberrant and accessory thyroid tissue. Hemiagenesis of the thyroid gland (THA) occurs when one half of the thyroid gland fails to develop. It is considered to be the rarest developmental abnormality of the

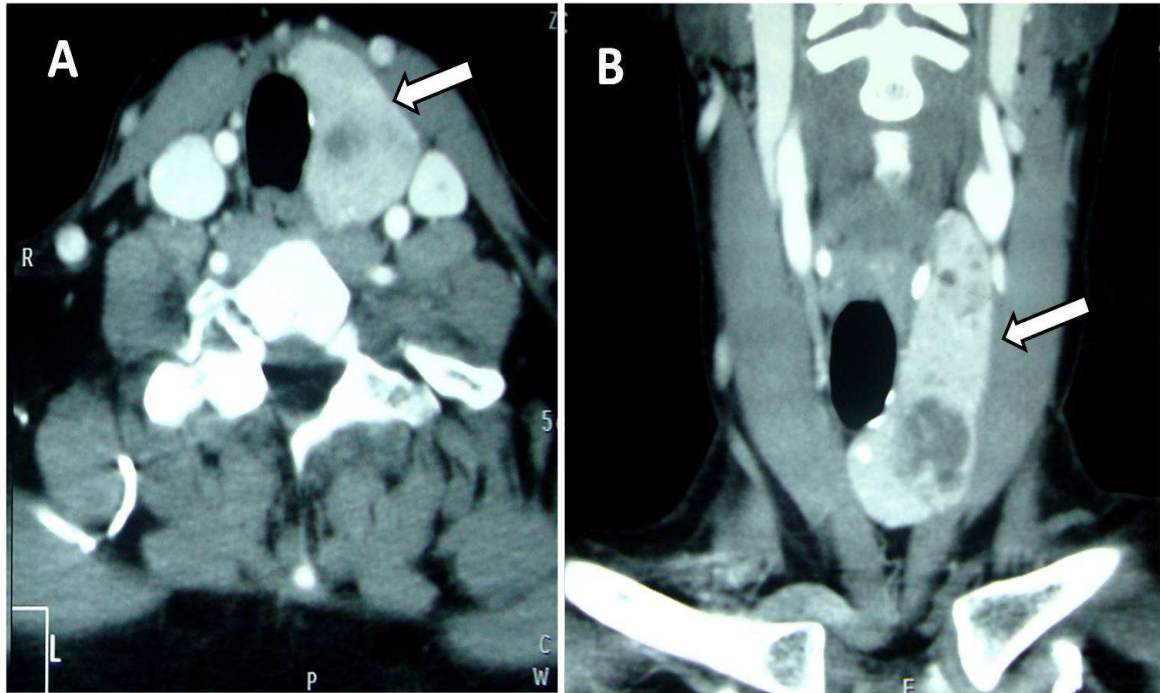
thyroid gland (McHenry et al, 1995). The exact incidence is unknown as often the patients may be clinically asymptomatic. The estimated prevalence is about 0.05 to 0.2% (Maiorana et al, 2003 and Shabana et al, 2000). Thyroid hemiagenesis anomaly was first described in 1852 by Handfield-Jones (Handfield Jones, 1852). Only about 310 cases have been reported in world literature to date (Tiwari et al, 2008).

## Case Report

A 36 year old female presented with a long standing goitre of fifteen years duration. Clinical examination revealed a palpable thyroid with multiple nodules on the left side and midline, while the right lobe was not palpable. She had no previous history of

neck surgery. The patient was clinically euthyroid, and thyroid function (*free T3, free T4 and TSH*) test was within normal limits. Ultrasonography showed multiple nodules in the left lobe of thyroid with a non visualized right lobe. Hence, a computed tomography scan was done which confirmed the absence of a right lobe (figure 1). Moreover, it did not reveal ectopic thyroid tissue. FNAC (fine needle aspiration

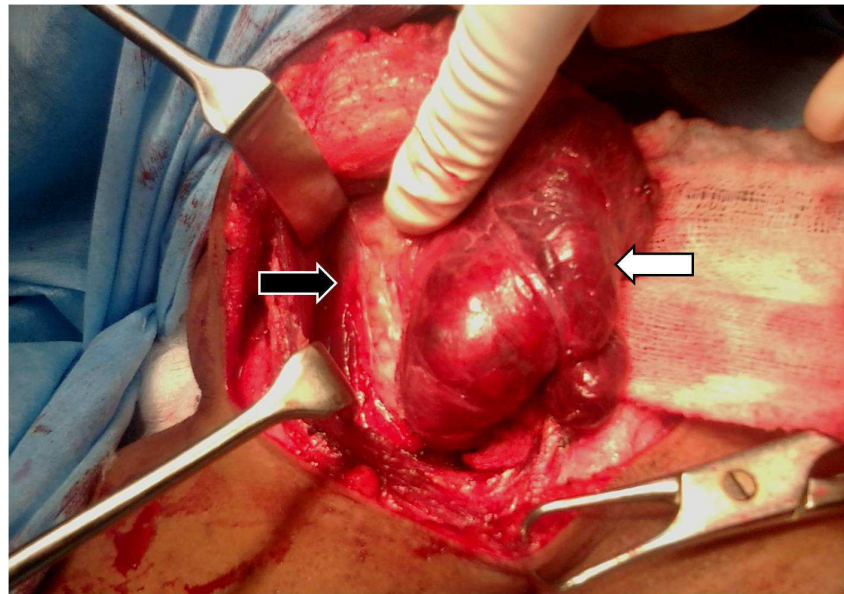
cytology) was suggestive of nodular colloid goitre with degenerative changes. Intra operative finding was a large left lobe with multiple nodules with a completely absent right lobe and isthmus. A total thyroidectomy (in this case a total left lobectomy) was done, as in our centre we routinely perform total thyroidectomy for multinodular goitres.



**Figure 1: Computed tomography scan of the neck showing absence of right lobe (hemiagenesis) with multiple nodules in the left lobe (white arrows).**

The right lobe and isthmus was absent [figure 2]. The strap muscles were lying directly over the tracheal rings on this side. The left lobe was multinodular with normal

anatomical relations with respect to the recurrent laryngeal nerve, thyroid vasculature and the parathyroids. The post operative period was uneventful.



**Figure 2: Operative image showing complete absence of the right thyroid lobe and isthmus. The right strap muscles and trachea is clearly visible (black arrow) and multiple nodules seen on the left lobe (white arrow).**

### Discussion

The exact aetiology for THA is not clear. During its development, the thyroid gland passes through an intricate process of migration, descent, lobulation and differentiation, which are orchestrated by various genetic and hormonal factors. Certain discrepancies of these complex regulatory mechanisms have been thought to be contributory towards the morphological and structural anomalies associated with THA. The development of the thyroid gland is controlled by a series of developmental transcription factors such as thyroid transcription factors (TTF) 1 (NKX2A), TTF-2 (FKHL15), and paired homeobox-8 (PAX-8) (De Felice and Di Lauro 2004). Mutations in these genetic factors are believed to be in a way responsible for thyroid dysgenesis and congenital hypothyroidism. In addition to these, the role of environmental factors has also been postulated (Ruchala et al. 2010). A genetic predisposition has also been suggested based on the reports of THA among monozygotic twins and occurrence with other familial thyroid malformation (Rajmil et al. 1984 and McLean et al 1985).

In many individuals, the normal thyroid gland is itself asymmetrical with the right lobe being larger than the left lobe, and therefore THA may be just an exaggeration of this effect. Suggested mechanisms include failure of bi-lobulation of the central anlage with all the thyroid tissue going over to one side of the midline, which may be brought about by environmental or genetic factors.

Hemiagenesis may involve either lobe, with or without agenesis of the isthmus. Studies carried out in living population showed that in about 80% of the cases it is the left lobe that is affected (Bergami et al 1995), and associated agenesis of the isthmus occurs in 50% of cases (Romanes 1981). However, studies on human cadavers show that the most common dysorganogenesis is the absence of isthmus followed by hemiagenesis. According to some investigators, the absence of isthmus is considered to be quite rare in humans. Hemiagenesis of the right lobe is also rare, with a left right ratio of 4:1. With right lobe agenesis, the isthmus too is most often absent.

By clinical examination alone, it may be difficult to accurately diagnose THA. Although the condition might mimic a

solitary nodule, careful examination will reveal that on the affected side the tracheal rings are easily palpable, and the edge of the sternomastoid may be nearer the midline.

Absence of uptake on the affected side in a thyroid scintiscan may raise the suspicion, and in such instances the differential diagnoses would include solitary toxic adenoma, primary or secondary neoplasms, unilateral inflammations and true hemiagenesis. Scintigraphy can be helpful in indentifying ectopic thyroid tissue. Ultrasound can easily establish the diagnosis in

suspected cases, and is considered by some as the investigation of choice in THA. CT and MRI are useful in distinguishing between unilateral thyroid disease and true hemiagenesis.

In areas where routine sonographical screening of thyroid is being performed, THA may be identified before they become symptomatic. The exact clinical significance of THA has been debated. However recent studies have shown that THA is more than just an anatomical curiosity. Gursoy et al (2008) and Ruchala et al (2010) have shown THA to be associated with an increased risk for developing thyroid disorders. The thyroid function may be altered in 38% to 47% of the cases. Disorders that have been reported in THA include hypothyroidism, hyperthyroidism, multinodular goitre, chronic thyroiditis, adenocarcinoma, and papillary carcinoma. The majority of these patients will however be euthyroid although hyperthyroidism is the most common abnormality in THA.

A total thyroidectomy (in this case a total left lobectomy) was done, as in our centre we routinely perform total thyroidectomy for multinodular goitres. We feel that total thyroidectomy is the procedure of choice for the surgical management of benign multinodular goiter, based on previous reports published from our region (Agarwal and Aggarwal 2008).

Whether earlier detection of THA might warrant regular screening or follow up or even prophylactic thyroidectomy in view of developing increased risk for thyroid disorders, based on recently published

reports, we feel, may be a topic for further research.

A high index of clinical suspicion based on the awareness of this condition may be helpful in identifying THA. In our patient, we initially suspected this to be a multinodular goitre with pathology confined to the left lobe with an impalpable (normal) right lobe. This article emphasizes that surgeons planning a thyroidectomy should be aware of the rare anatomical variations, so that these anomalies are not overlooked in the differential diagnosis, investigations and treatment.

### Conclusion

Right sided hemiagenesis is a rare developmental anomaly of the thyroid gland. A thorough understanding of thyroid anomalies is essential for the surgeon which should be complimented by appropriate radiological studies. More research needs to be done to study the association between hemiagenesis and other thyroid diseases.

### References

1. Agarwal G, and Aggarwal V(2008).”Is total thyroidectomy the surgical procedure of choice for benign multinodular goiter? An evidence-based review.” *World J Surg.* Jul;32:1313-24.
2. Bergami G, Barbuti D and DiMario M. (1995) “Echographic diagnosis of thyroid hemiagenesis” *Minerva Endocrinol* 20.3:195-8.
3. De Felice M and Di Lauro R. (2004)”Thyroid development and its disorders: genetics and molecular mechanisms” *Endocr Rev.*25:722-46.
4. Gursoy A, Anil C, Unal AD, Demirer AN, Tutuncu NB and Erdogan M. (2008) “Clinical and epidemiological characteristics of thyroid hemiagenesis: ultrasound screening in patients with thyroid disease and normal population,” *Endocrine* 33Endocrine 33 338-341.
5. Handfield Jones C: Thyroid gland. (1852) *The cyclopedia of anatomy and psihology.* Edited by Todd RB. London:

- 
- Longman, Brown, Green, Longmans & Roberts; 1103.
6. Jain A and Pathak S. (2010) "Rare developmental abnormalities of thyroid gland, especially multiple ectopia: A review and our experience", *Indian J Nucl Med* 25:143-146.
7. Maiorana R, Carta A, Floriddia G, Leonardi D, Buscema M, Sava L, Calaciura F and Vigneri R. (2003) "*Thyroid hemiagenesis: prevalence in normal children and effect on thyroid function*", *J Clin Endocrinol Metab* 88:1534-6
8. McHenry CR, Walfish PG, Rosen IB, Lawrence AM and Paloyan E. (1995) "Congenital thyroid hemiagenesis", *Am Surg* 61:634-639
9. McLean R, Howard N and Murray IP (1985). "Thyroid dysgenesis in monozygotic twins: variants identified by Scintigraphy" *Eur J Nucl Med*;10:346-8
10. Rajmil HO, Rodríguez-Espinosa J, Soldevila J, et al. (1984) "Thyroid hemiagenesis in two sisters", *J Endocrinol Invest*;7:393-4
11. Romanes GJ. *Cunningham's Textbook of Anatomy*. (1981) 12th ed. Oxford: Oxford University Press, 1981: 57-9, 286, 596-7.
12. Ruchala M, Szczepanek E, Szaflarski W, Moczko J, Czarnywojtek A, Pietz L, Nowicki M, Niedziela M, Zabel M, Köhrle J and Sowinski J. (2010) "Increased risk of thyroid pathology in patients with thyroid hemiagenesis: results of a large cohort case-control study", *Eur J Endocrinol*;162:153-160.
13. Shabana W, Delange F, Freson M, Osteaux M and De Schepper J. (2000) "*Prevalence of thyroid hemiagenesis: ultrasound screening in normal children*", *Eur J Pediatr* 159:456-458
14. Tiwari PK, Baxi M, Baxi J and Koirala D. (2008) "Right-sided hemiagenesis of the thyroid lobe and isthmus: A case report," *Indian J Radiol Imaging*;18:313-5.